CASE REPORT

Biclonal Primary Plasma Cell Leukemia

Zoltán TÓTH, József SIPOS

Department of Pathology, County Hospital of Zala, Zalaegerszeg, Hungary

Authors present a multiparameter pathological study in a case of rapid biclonal primary plasma cell leukemia. The immunohistochemical data revealed aberrant phenotypes (monocyte, epithelial and T-cell) probably in connection with microenvironmental influences. Biclonality can be attributed to class switching during malignant transformation. Static image cytometry showed aneuploidy. The blasts of this process are active immunoregulatory cells. (Pathology Oncology Research Vol 4, No 1, 48–51, 1998)

Key words: primary plasma cell leukaemia, biclonality, immunohistology, image cytometry

Introduction

The primary plasma cell leukemia (pPCL) is a rare malignant plasma cell proliferation, first diagnosed in the leukemic phase without the awareness of preexisting myeloma. The criterion for the diagnosis is an absolute plasma cell count of greater than 2G/l. A considerable number of cases with biclonal gammopathies have been described in various immunoproliferative disorders but only a few ones have demonstrated different immunoglobulins on tissue sections.[1,4,5,14,17,19] We report a case of a rapid biclonal pPCL with reference to immunohistological phenotype, proliferation markers, oncoproteins and ploidy pattern using static image cytometry.

Case report

Clinical history

19 year-old man was admitted to our hospital because of fever and fatigue lasting for a week. Physically, hepatosplenomegaly and generalized lymphadenopathy were found. Hematological findings were as follows: hemoglobin 66 G/l, platelets 84 G/l, WBC count 216 G/l with 96% blasts. Following our morphological and cytochemical diagnosis on blood smears and the introduction of chemotherapy, the patient died of cerebral bleeding within 48 hours. Serum immunoglobulin levels were not determined.

Autopsy findings

The examination was performed within 6 hours post mortem, revealing hepatosplenomegaly (liver 2270 g, spleen 930 g), generalized lymphadenomegaly, tumor-like nodules in the kidneys and a bright-red mass of bone marrow. The cause of death was cerebral bleeding. Post mortem histology demonstrated multiorgan blast cell infiltrations, including the brain, too.

Methods

Consecutively available samples were peripheral blood smears, marrow aspirats received in 10% buffered formalin and autopsy tissues. The smears were stained with May–Grünwald–Giemsa, periodic acid-Schiff (PAS), acid naphtylacetate esterase for myeloperoxidase, and immunocytochemically for kappa and lambda immunoglobulin light chains. The latter were carried out also on paraffin slides of marrow aspirate, firstly without enzymatic digestion and thereafter with pretreatment (0,2% trypsin in TBS working solution 2" at 20°C followed by an overnight incubation with primary antibodies at 4°C). The autopsy materials were fixed in 10% buffered formalin for 24 h. 4 μm paraffin sections were mounted on APES coated

Received: Dec 28, 1997; *accepted:* Febr 8, 1998

Correspondence: Zoltán TÓTH, M.D., Zrínyi út 1, 8901 Zalaegerszeg, Hungary

© 1998 W. B. Saunders & Company Ltd on behalf of the Arányi Lajos Foundation 1219-4956/98/010048+04 $ 12.00/0

glass slides and dried overnight at 37°C. Sections were depara ffinzed in xylene and hydrated through graded alcohol. Immunohistochemical reactions were accomplished in Sequenza (Shandon) slit capillary incubation chamber at room temperature according to the manufacturer's instructions, including microwave treatment and enzymatic digestion *(Table 1)*. Endogenous peroxidase was blocked with 3% H_2O_2 in methyl alcohol for 30 min at room temperature. Peroxidase activity was visualized with diaminobezindine (DAB, DAKO) and finally the sections were counterstained with haematoxyline. Several materials showed satisfactory internal control structures.

To measure the plasmablastic nuclear DNA content 8–10 micrometer kidney sections were stained according to the Feulgen method. The nuclei were examined under a Zeiss–Axioskop microscope coupled with a Sony television camera and a computerized image analyzer (Zeiss–Opton, Roche). This analyzer integrates optical density absorbance of the whole nucleus for each designated cell. DNA index (DI) was calculated as the ratio of the mean optical density of blastic nuclei to the mean optical density of control nuclei. DI was defined as diploid between 0,95 and 1,05. Tubular epithelial nuclei served as internal control (DI 0,96 and coefficient of variation 3,92). Evaluation of MIB 1 and PCNA positivity was performed using the quantitative immunohistochemistry software program (QICA) based on a double-colored imaging of positive and negative nuclei, respectively.

Results

Peripheral blood smears showed an acute blastic leukaemia with some plasmacytoid differentiation. The blasts were myeloperoxidase negative, PAS and acid

Table 1. **Immunohistological reactions**

Antibody/CD	*Major specificity*	*Dilution*	*Method*	*Source*
IgG[a]	heavy chain	1:80	LSAB	DAKO
IgA[a]	heavy chain	1:50	LSAB	DAKO
IgM[a]	heavy chain	1:20	LSAB	DAKO
kappa[a]	light chain	–	EPOS	DAKO
lambda[a]	light chain	–	EPOS	DAKO
CD 45[b]	leukocytes	–	EPOS	DAKO
HLA–DR[b]	B cell, active T, monocyte	1:50	LSAB	DAKO
CD 34[b]	haemopoetic progenitor	prediluted	LSAB	IMMUNOTECH
CD 45 RO[a]	T cell	1:100	LSAB	DAKO
CD 3[b]	T cell	–	LSAB	IMMUNOTECH
CD 4[b]	T subset	prediluted	LSAB	BIOGENEX
CD 8[b]	T subset	1:50	LSAB	DAKO
CD 20	B cell	–	EPOS	DAKO
CD 79a[b]	B cell	1:30	LSAB	DAKO
CD 68[a]	monocyte	–	EPOS	DAKO
Mac 387[a]	monocyte, myeloid	1:100	LSAB	DAKO
CD 61[a,b]	megakaryocyte	1:100	LSAB	DAKO
glycophorin A	erythroid	prediluted	LSAB	DAKO
cytokeratin[a]	epithelial	–	LSAB	DAKO
EMA	epithelial	–	EPOS	DAKO
CEA[a]	epithelial	1:50	LSAB	DAKO
vimentin[a]	mesenchyma	–	EPOS	DAKO
S–100[a]	neuroendocrine	–	EPOS	DAKO
Ki–67[b]	proliferation	1:100 L	LSAB	IMMUNOTECH
PCNA	proliferation	–	EPOS	DAKO
bcl–2[b]	oncoprotein	prediluted	LSAB	BIOGENEX
p53[b]	oncoprotein	1:100	LSAB	DAKO

EPOS – enhanced polymer staining; LSAB – labelled streptavidin–biotin; a – trypsin digestion; b – antigen retrieval with microwave in citrate buffer

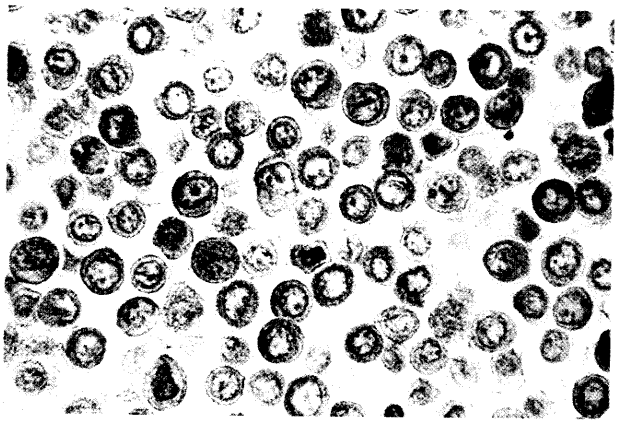

Figure 1. Kappa light-chain. Clot of blood. x1000

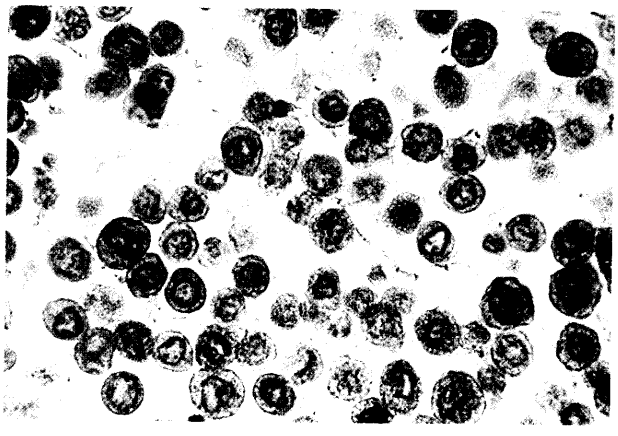

Figure 2. Lambda light-chain. x1000

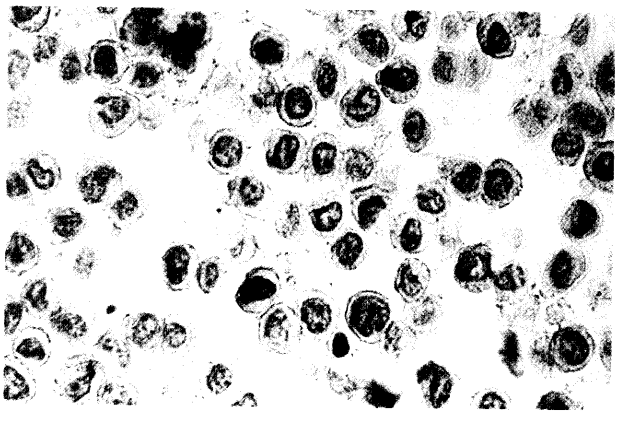

Figure 3. UCHL1 membrane staining. x1000

naphtylacetate esterase positive. Although both of the light-chain immunocytochemical reactions were positive on smears and in undigested paraffin sections of marrow aspirate, because of the strong intercellular background staining the clonality seemed to be equivocal. Nevertheless, on morphological grounds we diagnosed plasma cell

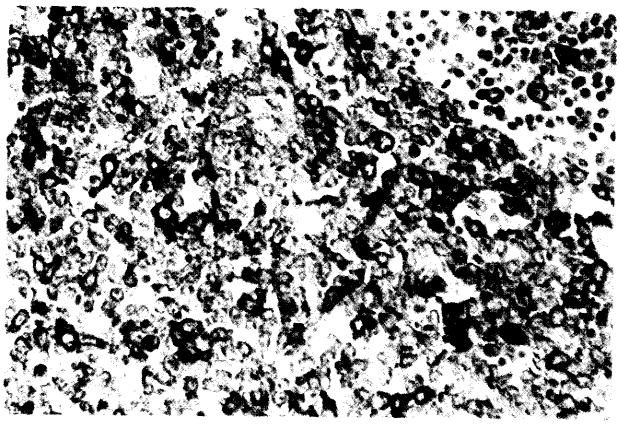

Figure 4. CD68 positive blasts in lymph node with remnant of follicle. x400

leukaemia. Doubtless, biclonal light-chain staining was first seen in autopsy material. In the sections of clot from the heart – containing only fully preserved plasmablasts and no serum background – both kappa *(Figure 1)* and lambda *(Figure 2)* cytoplasmic reactions appeared in about 50–50% of the leukaemic cells without any pretreatment. The same results were demonstrated in other organ infiltrations (kidney, lymph node, brain etc) with both mono- and polyclonal reagents. Finally, by trypsinizing the small remnant of original sections of bone marrow aspirate, an unequivocal biclonal reaction could be restored. The final immunohistological phenotype of plasmablasts was as follows: IgM^+(weak), IgG^+(weak), $kappa^+$, $lambda^+$, CD45S $(LCA)^+$, HLA-DR^+, CD45-RO $(UCHLI)^+$ *(Figure 3)*, CD68 (PG-Ml) *(Figure 4)*, pan-$cytokeratin^+$ (the latter in the bone marrow only, *Figure 5)*. Other hemopoietic and non-hemopoietic markers and apoptosis proteins were negative. MIB 1 and PCNA antibodies showed 12 and 18% nuclear staining, respectively, by quantitative immunohistochemistry. DNA cytometry indicated aneuploidy without any biclonal pattern.



Figure 5. Cytokeratin positive in filtrate in the bone marrow. x400

Discussion

This hyperacute and highly blastic manifestation is a curiosity in itself among the infrequent pPCL-s.[3] It is no wonder that similar multiparameter pathological investigations have been reported in myelomas only.[9] The initial diagnosis depends on the morphological recognition of the plasmocytoid features. Concerning biclonality, our suggestion is that neoplastic transformation evolved after the rearrangement of the μ-chain gene and kappa light-chain gene and was followed by class switching. The scene of this event could perhaps be the lymph node follicle.[6] In this respect, our heavily infiltrated nodal features with minimal follicular remnants were no longer informative. As for the existence of a single or double cell clone, our data are not satisfactory.

On the other hand, recently published immunocytochemical investigations uncovered multiple coexpressions of several hematological and non-hematological markers in neoplastic and reactive plasmacytoses.[9,13] These findings can lead to an initial misdiagnosis. For the cytokeratin positivity, ras oncogene can activate keratin transcription in non-epithelial tumors and there is evidence that messenger RNA for some keratins may be present ubiquitously.[7,20]

In addition to oncogene transactivation, phenotype heterogeneity can be attributed to immunomodulation, cytokine influences and adhesive effects, to which these active immunoregulatory cells are exposed in their microenvironment, especially in the bone marrow.[2,10,11,16,18] We could demonstrate cytokeratin in the marrow only and not in the clot or lymph node. Otherwise, the plasmablasts lacked CD34, glycophorin and CD61, thus – at least in our case – they were not descendants of a sequentially lineage-committed stem cell. As for the proliferation, our results are comparable with the few data reported by others in similar diseases,[12,15] albeit we used computer-assisted quantitative immunohistochemistry. Hypothetically, bcl-2 and p53 interaction prevents c-myc-induced apoptosis and renders myeloma cells resistant to chemo- and radiotherapy.[2] In our case, both apoptosis proteins proved to be negative.

The most common use of static image cytometry is the measurement of cellular DNA content (ploidy). Our histogram showed an aneuploid plasmablast population without any biclonal pattern. The independent prognostic value of aneuploidy is not fully established in myeloma.[8,21]

Acknowledgements

We thank Mrs Laczó, Mrs Matyovszky, Miss Pais and Mrs Sólyom for their excellent technical assistance.

References

1. *Berg AR, Weisenburger DD, Linder J et al:* Lymphoplasmacytic Lymphoma. Cancer 57:1794-1797, 1986.
2. *Feinman R, Sawyer J, Hardin J et al:* Cytogenetics and Molecular Genetics in Multiple Myeloma. Hematol/Oncol Clin North Amer 11: 1-25, 1997.
3. *Fülle HH, Pribilla W:* Diagnose und Therapie der Plasmazellenleukemie. Dtsch med Wschr 98: 874-881, 1973.
4. *Gerstein H, Budman DR, Schulman P et al:* Biclonal IgM Gammopathy in a Lymphoproliferative Disorder. Cancer 52: 824-827, 1983.
5. *Guarner J, Austin GE, Nassar V:* Biclonal Gammopathy (IgG and IgG) in a Patient With Non-Hodgkin's Lymphoma. Arch Pathol Lab Med 110: 445-448, 1986.
6. *Kelényi G:* Biology and pathology of plasma-cell tumors (In Hungarian). Magyar Belorvosi Archivum 1:32-38, 1997.
7. *Lasota J, Hyjek E, Koo CH et al:* Cytokeratin-positive Large-cell Lymphomas of B-cell Lineage. Amer J Surg Pathol 20:346-354, 1996.
8. *Leo E, Kropff M, Lindemanri A, et al:* DNA Aneuploidy Increased Proliferation and Nuclear Area of Plasma Cells in Monoclonal Gammopathy of Undetermined Significance and Multiple Myeloma. Anal Quant Cytol Histol 17: 113-119, 1995.
9. *Menke D, Horny H P, Sebo T, et al:* Use of Morphology, Immunophenotypic Aberrancy, Proliferation Indices, and Ploidy in the Prognostic Evaluation of Plasma Cell Neoplasms. Abstract. 84th Ann Meeting of US and Canad Acad Pathol, March 1117, 1995, Toronto. Modern Pathol 8: 116A, 1995.
10. *Munshi NC:* Immunoregulatory Mechanisms in Multiple Myeloma. Hematol/Oncol Clin North Amer 11: 51-69, 1997.
11. *Nishimoto 11T Shima Y, Yoshizaki K, et al:* Myeloma Biology and Therapy. Hematol/Oncol Clin North Amer 11: 159-172, 1997.
12. *Pellegrini W, Facchetti F, Marocolo D et al:* Assessment of cell proliferation in normal and pathological bone marrow biopsies: a study using double sequental immunophenotyping on paraffin sections. Histopathology 27: 397-405, 1995.
13. *Petruch UR, Horny H P, Kaiserling E:* Frequent expression of haemopoietic and non-haemopoietic antigens by neoplastic plasma cells: an immunohistochemical study using formalin-fixed, paraffin-embedded tissue. Histopathology 20:35-40, 1992.
14. *Schaffner KF', Krause JR, Kelly RH:* Biclonal IgM Gammopathy in Chronic Lymphocytic Leukemia. Arch Pathol Lab Med 112:206-208, 1988.
15. *Skopelitou A, Tselenis S, Theocharis S:* Expression of Proliferating Cell Nuclear Antigen (PCNA) and Nucleolar Organizer Regions (NORs) in Multiple Myeloma. Anticancer Res 14: 787-792, 1994.
16. *Teoh G, Anderson K:* Interaction of Tumor and Host Cells With Adhesion and Extracellular Matrix Molecules in the Development of Multiple Myeloma. Hematol/Oncol Clin North Amer 11: 27-42, 1997.
17. *Yatable Y, Mori N, Oka K et al:* A Case With Primary Gastric Lymphoma Producing IgM and IgG Immunoglobulins. Arch Pathol Lab Med 118: 655-658, 1994.
18. *Yi Q, Dabadhghao S, Österborg A et al:* Myeloma Bone Marrow Plasma Cells: Evidence for Their Capacity as Antigen-Presenting Cells. Blood 90: 1960-1967, 1997
19. *White V, Boyko WJ:* Chronic Lymphotic Leukemia With IgM and IgG Cytoplasmic Inclusions. Arch Pathol Lab Med 107: 580-582, 1983.
20. *Wotherspoon AC, Norton AJ, Isaacson PG:* Immunoreactive cytokeratins in plasmacytomas Histopathology 14: 141-150, 1989.
21. *Zandecki M, Bernardi F, Lai JL:* Image Analysis in Multiple Myeloma at Diagnosis. Cancer Genet Cytogenet 74: 115-119, 1994.