

## ARTICLE

## Vascularization Pattern of C6 Glioma is Modified with Medroxyprogesterone Acetate and Ibuprofen in Wistar Rat Brain

Meric A ALTINOZ,<sup>1</sup> Engin OZAR,<sup>3</sup> Murat TASKIN,<sup>3</sup> Evin BOZCALI,<sup>1</sup> Ayhan BILIR,<sup>1</sup> Tuncay ALTUG,<sup>2</sup> Adnan AYDINER,<sup>2</sup> Aydin SAV<sup>4</sup>

<sup>1</sup>Department of Histology and Embryology,<sup>2</sup>Institute of Oncology, Faculty of Medicine, Istanbul University;

<sup>3</sup>1<sup>st</sup> Neurosurgery Clinic in Bakirkoy Mental Diseases Hospital, <sup>4</sup>Talia Bali Aykan Neuropathology Laboratory at Institute of Neuroscience at Marmara University

**Beneficial effects of medroxyprogesterone acetate (MPA) in cancer therapy is partly mediated via its antiangiogenic activity. The same is true for the antitumoral action of non-steroidal antiinflammatory drugs. We have studied two liposoluble drugs, MPA and the analgesic ibuprofen, on glioma vascularization *in vivo*. In this study we have shown that, until the sacrifice at 27. day after tumor inoculation in the right hemisphere, MPA had a slight though insignificant activity to reduce the fatality of C6 glioma, growing in right cerebral hemisphere of male Wistar**

**rats. But ibuprofen both alone or with MPA had no effect on survival with gavage application of a 30 mg/kg/day dosing regime. On histological analysis, intra- and peritumoral vessels were counted. Progesterone seemed to lower intratumoral, but to increase peritumoral vessels, especially glomeruloids, around the tumor mass. Coadministration of ibuprofen acted to suppress the peritumoral vessel increase, and to enhance lymphomonocytic infiltration around tumor vessels. (Pathology Oncology Research Vol 7, No 3, 185–189, 2001)**

**Keywords:** medroxyprogesterone, ibuprofen, glioma, angiogenesis

### Introduction

The progesterone analogue and depot contraceptive MPA was found to be inhibitory for *in vivo* angiogenesis of subcutaneously implanted C6 glioma cells in agarose beads into C57BL/6 mice.<sup>15</sup> Moreover, 17-alpha-hydroxy progesterone is inversely correlated with the angiogenesis of human spinal tumors.<sup>17</sup> MPA reduces secondary spreading of human gynecological cancer cell lines and angiogenesis of endometrial cancer cells by decreasing fibroblastic growth factor.<sup>5</sup> But more recent studies indicated that MPA can induce vascular endothelial growth factor (VEGF) production in human human breast cancer cells.<sup>8</sup> This discrepancy suggested that more studies should be done in the field of chemoenocrine therapy also in the central nervous system

tumors as well. In this study we investigated the effects of systemic MPA application on C6 gliomas implanted by microinjection into Wistar rat brains. A well known analgesic ibuprofen was found to inhibit C6 glioma spheroid growth in Sprague-Dawley rat brains by systemic application, without inhibiting its proliferation *in vitro*.<sup>4</sup> Ibuprofen was given in combination with MPA to another group of rats bearing C6 glioma, to observe any possible benefit.

### Materials and Methods

#### Cell line

The C6 glioma cell line was obtained from ATCC (Rockville, USA) and serial passages were made at the Histology and Embryology Department of Istanbul Medical School in modified Eagle medium of Dulbecco, which contained 15% heat inactivated fetal calf serum, 0.2 mM glutamine, 50 mg/ml neomycin, and 100 mg/ml streptomycin. Culture flasks were kept in electronic incubator (Sanyo) under humidified atmosphere with 5% CO<sub>2</sub> at 37°C. Implantation procedure: cells were harvested

Received: April 27, 2001; revised: Sept 2, 2001; accepted: Sept 10, 2001;

Correspondence: Meric A ALTINOZ, MD; General Sukru Kanatli Sok. No: 36/8, Bakirkoy/Istanbul; Tel: 90-212-570 7743, fax: 90-212-511 7871; E-mail address: maltinoz@hotmail.com

via 2 ml trypsin- EDTA solution C (Biological Industries, Israel) and centrifuged after the addition of 1.5 cc of F12 medium and fetal calf serum mixture at  $1 \times 10^3$  rpm for three minutes. After removing the supernatant, pellet was resuspended with 2 cc of medium. Cell suspension was concentrated; so that 5 microliters of any injection volume would contain  $5 \times 10^5$  cells, and then placed in a microcentrifuge tube, and kept in a water-ice mixture environment during the whole implantation procedure, which always lasted less than 2 hours. Male Wistar rats, weighing between 220 and 280 grams, were anesthetized by intramuscular injection of a solution containing 42.8 mg/ml of 10% ketamine and 8.6 mg/ml of 2% xylazine (this dosage did not exceed 0.7 mg/kg of body weight in total). The rats were secured into a stereotaxis apparatus (Trent Welles Inc., South Gate, Ca, USA). After antiseptic preparation of the scalp with betadine, the skin was incised on the mid-sagittal line for 1 cm. A burrhole (1.5 mm wide) was made on the right side 3 mm lateral to midline, and 2 mm proximal to the bregma using a dental drill. Injection of the C6 glioma cell suspension was made using a Hamilton syringe with a 27 gauge needle, which was fixed to the manipulation arm of the stereotaxis apparatus and advanced to the center of the right caudate nucleus which was 5 mm deep to the surface of the brain. A total of 5  $\mu$ l solution was injected over a 5 minute of time in 0.5  $\mu$ l aliquo. The needle was kept in same place for an additional 3 minutes and then withdrawn very gently over 2 minutes. The operation area was irrigated with saline and the burrhole was covered with bone-wax. The scalp was sutured using 5-0 vicryl.

#### *Drug treatment, groups and monitorization*

There were 7 rats in each of the three groups which were fed *ad libitum*. After 11<sup>th</sup> day of implantation, control groups were began a sham treatment with saline both by gavage and intraperitoneal injections. MPA treatment group animals were given 1 mg/kg i.p. injections of MPA (Farlutal, Deva<sup>®</sup>); MPA and ibuprofen combination therapy group were given 30 mg /kg ibuprofen (Brufen<sup>®</sup> syrup, Eczacibasi) by gastric catheter (6<sup>°</sup>F) in addition to 1 mg/kg MPA ip injections. All sham and experimental treatments were done daily until sacrifice. All rats

were monitored daily for any focal motor deficits, bradykinesia or any other major neurologic symptoms. On the 14<sup>th</sup> or 15<sup>th</sup> day of the inoculation, most of the rats developed left hemiparesis and bradykinesia. On the 22<sup>nd</sup> day of experiment one randomly selected rat from each group was examined by magnetic resonance imaging. T2 weighted images showed a tumoral mass and peritumoral edema in the right hemisphere (data not shown). On the 27<sup>th</sup> day of experiment, all rats were decapitated under anesthesia for further evaluation.

#### *Histopathological evaluation*

Brains fixed in 10% buffered formalin were dissected in 10 mm coronal slices via taking inoculation hole as origin. All samples were photographed. Glass slides of 4 microns thickness were prepared. Histology sections from these were stained with conventional haematoxylin-eosin technique for routine analysis. For further analysis immunohistochemistry was applied. Monoclonal markers for GFAP and CD34 expression were made via streptavidine immunohistochemistry. Number of intra-/ peri-tumoral vessels and glomeruloid microendothelial proliferations were counted in five HPF area (0,238 mm<sup>2</sup>); according to these data, two indexes were calculated,  $i_1$  and  $i_2$  respectively.  $i_1$  = Intratumoral vessel number / total tumor area,  $i_2$  = Peritumoral vessel number / intratumoral vessel number.

#### *Statistics*

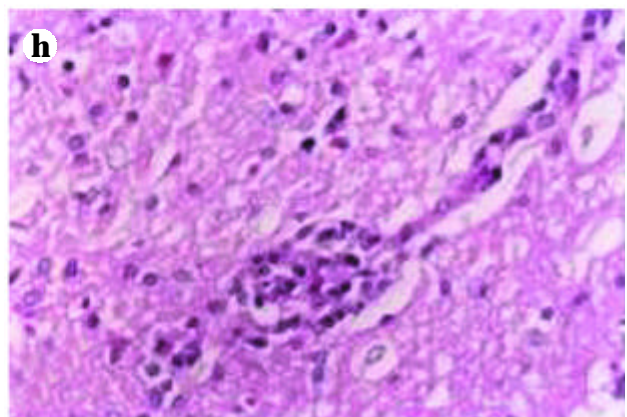
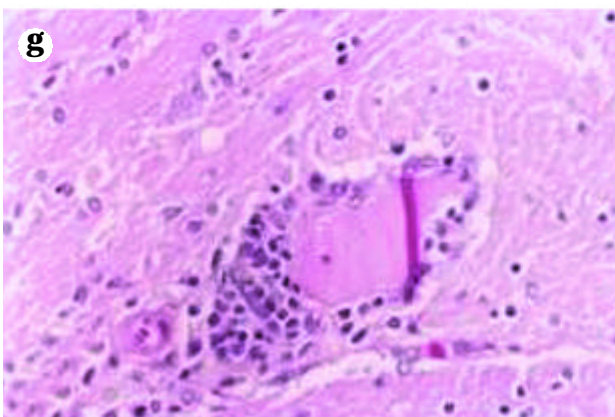
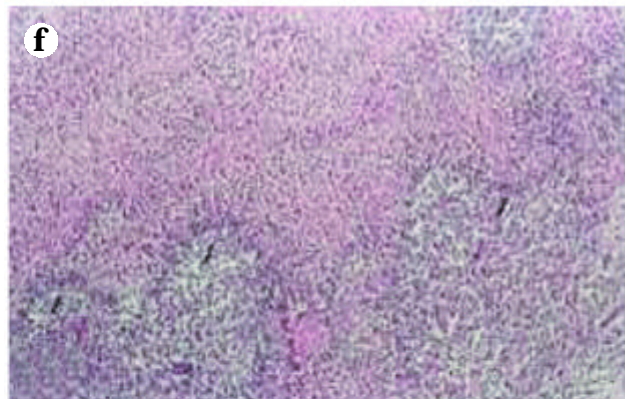
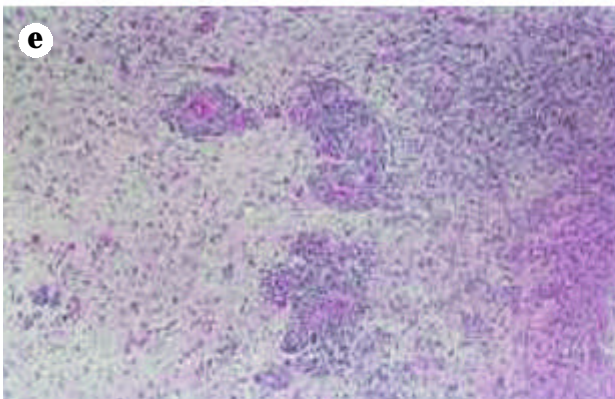
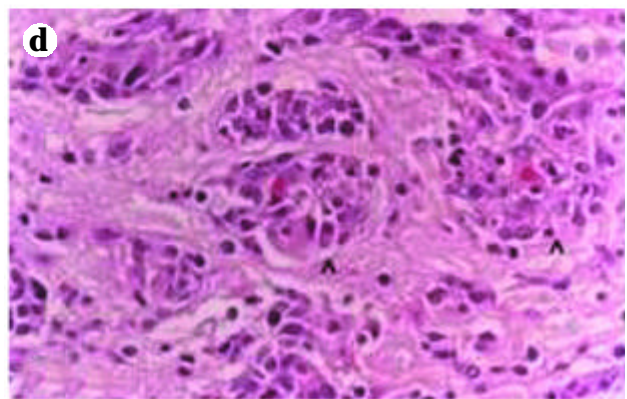
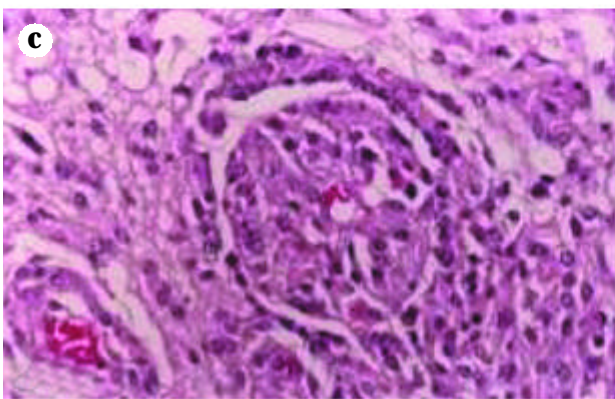
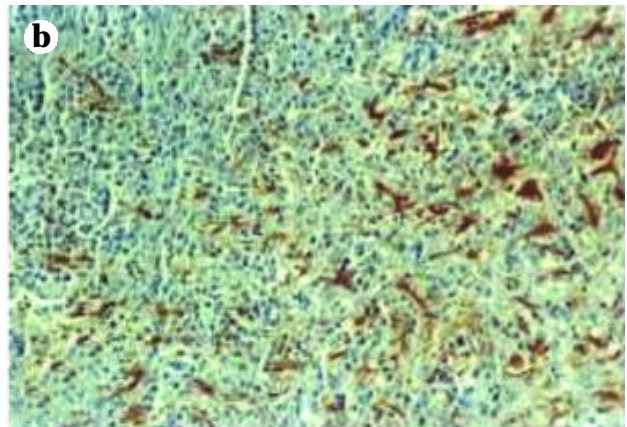
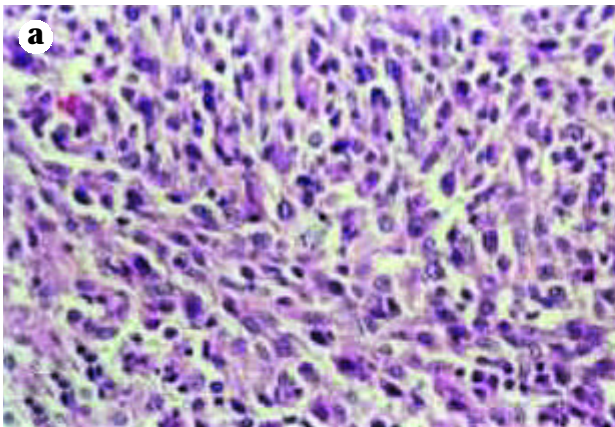
Statistical analysis of survival until the sacrifice was made via Wilcoxon test.

#### *Results*

##### *Survival*

Progesterone treated animals tend to die later than the control group especially in the early term, but later the survival ratio was equal in all groups (data not shown). Overall survival until the day of sacrifice was not found statistically significant between all groups, but the p value of 0.087 (according to Wilcoxon test) between control and progesterone group, may suggest a trend to significance in a larger experimental group.

**Figure 1.** (a) Control group (x100). All tumors examined contained pleomorphic cells, mostly with vesicular nuclei and abundant eosinophilic cytoplasm; mitotic figures and atypical nuclei were widespread (small asterisk in the center). (b) MPA treated group (x100). Tumoral tissue was stained sparsely with GFAP. (c) A glomeruloid (g) in MPA treated group (x400). Note the structures resembling to Bowman capsule (b), afferent pole (p) and the erythrocyte (e) in the glomeruloid center. (d) Vascular endothelial proliferation in MPA treated group (x400). (e) Lymphomonocytic infiltration around peritumoral vessels after single ibuprofen treatment (x100). (f) Necrosis with pseudopalisading in control group (x100). (g) Lymphomonocytic infiltration around tumor vessels in MPA and ibuprofen combination group (x400). (h) MPA and ibuprofen combination group (x400). Glomeruloids were fewer and distorted.



### *Histopathological evaluation and parameters of vascularization*

All tumors contained pleomorphic cellular elements, mostly with vesicular nuclei and bundant eosinophilic cytoplasm; mitotic figures and atypical nuclei were widespread, as well as necrosis with pseudopalisading (*Figure 1a, f*). Tumoral tissue was stained only sparsely with GFAP (*Figure 1b*). CD34 expression was not observed in the tumor endothelium, using positive controls via staining of vessels in a rodent lymph node (data not shown). Control group tumors contained more intratumoral vessels than the treatment groups; and all the vessels were shown little evidence of endothelial proliferation, moreover glomeruloid epithelial proliferations were almost absent. Progesterone group contained frequent figures of endothelial proliferations both in peri- and intratumoral area and enhanced level of glomeruloid formations (*Figure 1c, 1d*).

Vascularization was localized in the transition zone of the tumor and brain parenchyma. In progesterone and ibuprofen combination group, tumoral lymphomonocytic infiltration tended to be more than the control or progesterone alone (*Figure 2g*). Such infiltrations were even more prominent in group under single ibuprofen treatment (*Figure 2e*). Though progesterone and progesterone and ibuprofen combination group had comparable tumor diameters (data not shown), microendothelial proliferation was less. Moreover glomeruloid bodies were few and rudimentary in the latter one (*Figure 2h*). Due to a small group of surviving animals, the indices of vascularization described above were not statistically significant. But major changes observed were as follows: intratumoral vascularization in the control group tend to correlate more strongly with total tumor area with  $i_1$  indexes of 5.73 and 2.54 and more intratumoral vessel figures, whereas this correlation was lower in the progesterone group with  $i_1$  values of 1.27, 1.58 and 2.54 respectively. Ibuprofen progesterone combination had  $i_1$  indexes of 2.09, 1.35, 2.07, and 4.24. Peritumoral versus intratumoral vessel ratio was low in the control group with  $i_2$  indexes of 0.5 and 0.72, whereas peritumoral vessel number was greater in the progesterone group with  $i_2$  indexes of 0.79, 4.36, 1.32, 2.22. The vascularization pattern of ibuprofen and progesterone combination was between the control and progesterone alone group, with  $i_2$  indexes of 1.13, 1.30, 1.29, 1.30.

### *Discussion*

Evaluation of a mesenchymal score, analysing vascularization intensities, endothelial proliferation and number of glomeruloids, together with a conventional nuclear score, can strongly predict the prognosis of malignant glial human tumors.<sup>18</sup> Glomeruloid vascular proliferation has been shown also in ethylnitrosourea-induced rodent glial

tumors.<sup>22</sup> Among all other vascular types, most intensive staining with bromodeoxyuridine is evident in glomeruloids of rodent<sup>22</sup> as well as human<sup>13</sup> glial tumors. Glomeruloids may be ontogenetic relatives of kidney glomeruli, since glomeruloids bear vascular endothelium and vascular smooth muscle specific staining in glioblastoma and gliosarcoma<sup>7,8,20</sup> as do normal glomeruli, and glioma mesenchymal extracellular matrix antigen gives a positive reaction both with kidney glomeruli and glioma glomeruloids.<sup>2</sup> Moreover, mouse alloantigen Ia.20 specific antibodies bind kidney glomerul epithelia and smooth muscle cells as well as a glioma cell line with similar pattern.<sup>21</sup> Glioma glomeruloids are intensively stained with plasminogen activator inhibitor-1 (PAI-1).<sup>12</sup> The antiangiogenic action of progesterone is also mediated via increasing plasminogen activator inhibitor (PAI) levels and subsequent inhibition of plasminogen activator (PA).<sup>1</sup> But in our model MPA has increased peritumoral vascularization, especially glomeruloid microendothelial proliferation in peritumoral area.

Progesterone might differentially affect glioma angiogenesis, since gliomas and surrounding vessels express the progesterone receptor in correlation with their grade.<sup>12</sup> It is unlikely that PAI is a negative regulatory factor for glomeruloids. In normal glomerular mesangium, endothelial proliferating factors, endothelin-1 and renin increase PAI release in kidney glomeruli.<sup>9,14</sup> But there is no direct evidence as yet, that PAI is an autocrine growth enhancer for glomeruloid or normal glomerul endothelia. New studies should be done if progesterone induces PAI, and this leads to an accelerating effect on glioma glomeruloids. Looking to the effects of ibuprofen, due to gavage complications there were not enough animals to analyze its single effects in detail, but ibuprofen always tended to act to increase peritumoral lymphomonocytic infiltration, which may be explained by the decrease in immunosuppressive prostaglandins.<sup>5</sup> Another interesting property is that it also supresses the peritumoral vessel and glomeruloid increase in MPA treated animals. Ibuprofen could upregulate PA,<sup>4</sup> and down regulate VEGF,<sup>16</sup> both effects in opposition to MPA. Analysis of the modulation of PAI / PA, and VEGF synthesis with steroidal and non-steroidal anti-inflammatory drugs, and their impact on tumoral angiogenesis and glomeruloid formation, may give important clues for glioma treatment.

### *References*

- <sup>1,2</sup>Blei F, Wilson EL, Mignatti P, et al: Mechanism of action of angiostatic steroids: Suppression of plasminogen activator activity via stimulation of plasminogen activator inhibitor synthesis. *J Cell Physiology* 155:568-578, 1993.
- <sup>2</sup>Bourdon MA, Wikstrand CJ, Furthmayr H, et al: Human glioma-mesenchymal extracellular matrix antigen defined by monoclonal antibody. *Cancer Res* 43:2796-2805, 1983.

- 3.<sup>2</sup>*Chow G, Woronick A, Kinkade P, et al*: Pharmacological modulation of plasminogen activator secretion by P388D1 cell line. *Agents Actions* 21:387-389, 1987.
- 4.<sup>2</sup>*Farrell CL, Megyesi JM, Maestro FRD*: Effect of ibuprofen on tumor growth in the C6 spheroid implantation glioma model. *J Neurosurg* 68:925-930, 1998.
- 5.<sup>2</sup>*Fujimoto J, Hosoda S, Fujita H, et al*: Effect of medroxyprogesterone acetate on secondary spreading of endometrial cancer. *Invasion Metastasis* 9:209-215, 1989.
- 6.<sup>2</sup>*Haddad SF, Moore SA, Schelper RL, et al*: Smooth muscle can comprise the sarcomatous component of gliosarcomas. *J Neuropathol Exp Neurol* 51:493-498, 1992.
- 7.<sup>2</sup>*Haddad SF, Moore SA, Schelper RL, et al*: Vascular smooth muscle hyperplasia underlies the formation of glomeruloid vascular structures of glioblastoma multiforme. *J Neuropathol Exp Neurol* 51:493-498, 1992.
- 8.<sup>2</sup>*Hyder SM, Murthy L, Stancel GM, et al*: Progestin regulation of vascular endothelial growth factor in human breast cancer cells. *Cancer Res* 58:392-395, 1998.
- 9.<sup>2</sup>*Iwamoto T, Tamaki K, Nakayama M, et al*: Effect of endothelin 1 on fibrinolysis and plasminogen activator inhibitor 1 synthesis in rat mesangial cells. *Nephron* 73:273-297, 1996.
- 10.<sup>2</sup>*Jikihara H., Terada N., Yamamoto R., et al*: Inhibitory effect of medroxyprogesterone acetate on angiogenesis induced by human endometrial cancer. *Am J Obstet Gynecol* 167:207-211, 1992.
- 11.<sup>2</sup>*Khalid H, Shibata S, Kishikawa M, et al*: Immunohistochemical analysis progesterone receptor and Ki-67 labelling index in astrocytic tumors. *Cancer* 80:2133-2140, 1997.
- 12.<sup>2</sup>*Kono S, Rao JS, Bruner JM, et al*: Immunohistochemical localization of plasminogen activator type 1 in human brain tumors. *J Neuropathol Exp Neurol* 53:256-262, 1994.
- 13.<sup>2</sup>*Nagashima T, Hoshino T, Cho KG*: Proliferative potential of vascular components in human glioblastoma multiforme. *Acta Neuropathol* 73:301-305, 1987.
- 14.<sup>2</sup>*Nguyen G, Delarue F, Berrou J, et al*: Specific receptor binding of renin on human mesangial cells in culture increases plasminogen activator inhibitor-1 antigen. *Kidney Int* 50:1897-1903, 1996.
- 15.<sup>2</sup>*Okada N, Fushimi M, Nagata Y et al*: Evaluation of angiogenic inhibitors with an in vivo quantitative angiogenesis method using agarose microencapsulation and mouse hemoglobin enzyme-linked immunosorbent assay. *Jap J Cancer Res* 87:952-957, 1996.
- 16.<sup>2</sup>*Palayoor ST, Bump EA, Calderwood SK, et al*: Combined anti-tumor effect of radiation and ibuprofen in human prostate carcinoma cells. *Clin Canc Res* 4:763-771, 1998.
- 17.<sup>2</sup>*Rao BR*: Pregnancy associated highly vascularized tumors negatively correlate with the levels of antiangiogenic 17 alpha-hydroxy-progesterone. *Anticancer Res* 17:1019-1021, 1999.
- 18.<sup>2</sup>*Ritten EH, Doesburg WH, Slooff JL*: Histologic factors in the grading and prognosis of astrocytoma grade I-IV. *J Neurooncol* 13:223-230, 1992.
- 19.<sup>2</sup>*Selby DM, Woodard CA, Henry ML, et al*: Are endothelial cell patterns indicative of grade. *In vivo* 11:371-375, 1997.
- 20.<sup>2</sup>*Slowik F, Jellinger K, Gaszo L, et al*: Gliosarcomas: histological, immunohistochemical, ultrastructural, and tissue culture studies. *Acta Neuropathol(Berl)*, 67:201-210, 1985.
- 21.<sup>2</sup>*Wadgymar A, Halloran PF*: Crossreactions between an I-A allospecificity and the cytoskeleton of glomerular epithelium and of vascular smooth muscle. *Transplantation* 43:93-98, 1987.
- 22.<sup>2</sup>*Yoshida Y, Kumanishi T, Abe S*: Glomeruloid blood vessels in ethylnitrosourea-induced rat gliomas. Histological and immunohistochemical studies. *Acta Neuropathol* 79:240-247, 1989.