

## ARTICLE

## Her-2/*neu* Gene Amplification Compared with HER-2/*neu* Protein Overexpression on Ultrasound Guided Core-Needle Biopsy Specimens of Breast Carcinoma

Handan KAYA,<sup>1</sup> Teresa RAGAZZINI,<sup>2</sup> Erkin ARIBAL,<sup>3</sup> Ýter GÜNEY,<sup>4</sup> Esin KOTILOĐLU<sup>1</sup>

<sup>1</sup>Department of Pathology, <sup>3</sup>Department of Radiology, <sup>4</sup>Department of Medical Biology, Marmara University Hospital, Istanbul; <sup>2</sup>Department of Oncology, University of Bologna, Italy

**Genomic amplification and oncoprotein overexpression of Her-2/*neu* was studied on ultrasound core needle biopsy specimens of the infiltrative ductal carcinomas of the breast. We performed “two colour” fluorescence in situ hybridization (FISH) for Her-2/*neu* and chromosome 17 and compared the FISH results with the immunohistochemical overexpression of Her-2/*neu* protein by 2 antibodies (DAKO HercepTest and the BioGenex monoclonal antibody AM 134-5M). Furthermore, following radical mastectomy with axillary dissection, Her-2/*neu* status of the patients were compared with the well known histopathological prognostic factors such as histo-**

**Keywords:** breast carcinoma, FISH, immunohistochemistry, Her-2/*neu*

**logic grade, tumor stage, lympho/vascular invasion, surgical margin status and Paget’s disease. Amplification was demonstrated 27% of the cases. Her-2/*neu* protein overexpression was detected in 47% and 80% of the cases with CB11 and HercepTest respectively. We revealed statistically significant association between the tumor, oncoprotein expression and oncogene amplification ( $p < 0.05$ ). The results of our study showed that combination of IHC and FISH methods enhances the evaluation of tumor genetics at both gene and protein level for the analysis of Her-2/*neu* in breast carcinoma. (Pathology Oncology Research Vol 7, No 4, 279–283, 2001)**

### Introduction

Ultrasound (US) guided core-needle biopsy of breast (CNB) is increasingly used for the diagnosis of breast lesions and is demonstrated to be highly sensitive and specific for the diagnosis of carcinomas.<sup>1,2</sup> It is also shown that immunostaining results for bcl-2, ER, c-erbB-2 and p53 on the CNB and the corresponding excision specimens are 100% concordant.<sup>3</sup>

Her-2/*neu* (c-erb-B2) is an oncogene related to epidermal growth factor receptor family.<sup>4</sup> It is overexpressed on a subset of in situ and invasive carcinomas of the breast.<sup>5,6</sup> In 90% of the cases Her-2/*neu* protein overexpression is caused by gene amplification, and is shown to be independently associated with poor prognosis in women with

node-positive breast cancer.<sup>7</sup> Genomic amplification is usually associated with increased expression of messenger RNA and the encoded oncoprotein.<sup>8-15</sup> However discordance between expression and genomic amplification occurs in about 3 to 15% of cases.<sup>9,13,16</sup> The clinical significance of lower levels of immunoeexpression (2) and such discordance between genomic amplification and oncoprotein expression still remains uncertain.<sup>9,12,13,16</sup> The aim of this study was (i) to search the concordance between genomic amplification and oncoprotein expression of Her-2/*neu* (ii) to evaluate the correlation between Her-2/*neu* and status with other prognostic factors such as histologic grade, tumor stage, lympho/vascular invasion, surgical margin status and Paget’s disease.

### Materials and Methods

We studied 15 patients who had a US guided breast CNB with a diagnosis of infiltrative ductal carcinoma followed by mastectomy and axilla dissection. The median

Received: Nov 9, 2001; accepted: Nov 20, 2001

Correspondence: Handan KAYA, MD, Department of Pathology, Marmara University Hospital, 81190, Altunizade, Istanbul, Turkey; Tel/fax:90 216 3271905; e-mail: hkaya@superonline.com

time to radical mastectomy was 21 days (range, 7-42 days). Patients received no radiation therapy or chemotherapy between the US guided CNB and the radical mastectomy. CNB was performed free hand with a 14 gauge needle biopsy gun (Magnum Bard Covington Ga) under US guidance. FISH and immunohistochemistry techniques were applied to CNB specimens. Clinical data was collected from patient records, tumors were staged according to TNM (1999) classification and histological grading was done according to World Health Organization recommendations. Complete data is presented in *Table 1*.

#### DNA Probes

The following fluorophore-labeled locus specific identifier (LSI) DNA probes were used: LSI HER-2/*neu* DNA Spectrum Orange/ CEP17 Spectrum Green (Vysis), LSI/WCP hybridization (Dextran sulphate, formamide, SSC).

#### Fluorescence in situ hybridization

We performed fluorescence in situ hybridization analysis on 5 µm serial sections of the selected cases. Sections were dewaxed in xylene (2X5 min), rinsed in 100% ethanol (2X5 min) and air-dried. Prior to FISH, the slides were placed in a plastic Coplin jar filled with PBS for 5 minutes and dehydrated in ethanols (70%, 80%, and 90%). After air drying, sections were pre-treated by 2X standard saline citrate (SSC) for 30 min at 37°C, followed by 0.01 NHCL 100 µl pepsin treatment for 10 min at 37°C. 2X SSC treatment was applied at room temperature for 5 min. Then sections were placed in a plastic Coplin jar filled with denaturation solution (70% formamide/2X SSC) at 73°C for 5 min, followed by dehydration in ethanol (70%, 80%, 90%). The prewarmed probe was applied to the target area on slides followed by placement in a prewarmed humidified chamber in a 37°C incubator for 12 hours. After hybridization, the slides were washed in 0.4X SSC/0.3% NP-40 mixture for 2 minutes and then in 0.4X SSC/0.1% NP-40 at 73°C for 2 seconds. The slides were counterstained with 4,6-diamidino-2-phenylindole (DAPI) and a coverslip was applied.

#### Evaluation

An Olympus BX 40 fluorescence microscope was used for scoring signal copy numbers from a minimum of 40 nuclei per hybridization for each probe from the previously mapped carcinomatous foci. One pattern consisted of two orange and two green signals, reflecting a normal disomic complement for both HER-2/*neu* and centromere 17. HER-2/*neu* gene copy amplification was classified as absent (one to four gene copies), borderline (four to eight gene copies), or positive/present (more

**Table 1. Clinical Data, Immunohistochemistry and FISH**

Case	Age	G	Stage	L/V	Paget's	EM	Bio	Hercept	HER-2
1	66	2	T2N0	-	-	-	+	+++	A
2	38	2	T1N1	+	-	-	++	+++	A
3	47	3	T3N0		+	-	++	+++	A
4	55	1	T1N0	-	-	-	-	+	-
5	56	2	T2N0	-	-	-	-	-	-
6	72	2	T1N0	-	-	-	-	-	-
7	50	2	T1N0	+	-	-	-	+	-
8	36	2	T1N1	-	-	-	+	+++	-
9	63	2	T2N1	-	-	-	-	++	-
10	64	1	T1N0	-	-	-	+	+++	A
11	64	2	T1N0	-	-	-	+	+	-
12	79	2	T1N0	-	-	-	-	-	-
13	67	2	T2N1	-	-	-	+	+	-
14	73	2	T1N0	-	-	+	-	++	-
15	65	2	T2N0	-	-	-	-	++	-

G: Grade; EM: Excision margins; L/V: Lympho/vascular invasion; A: Amplification

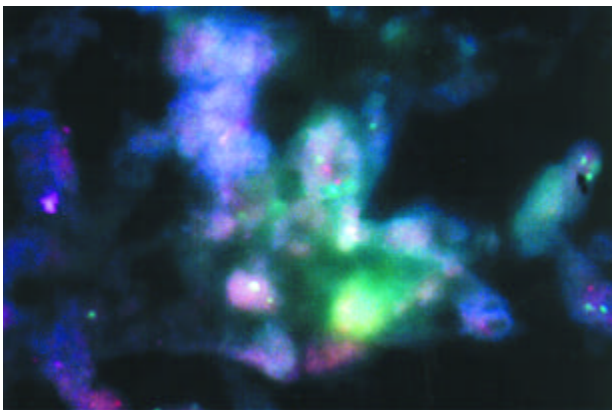
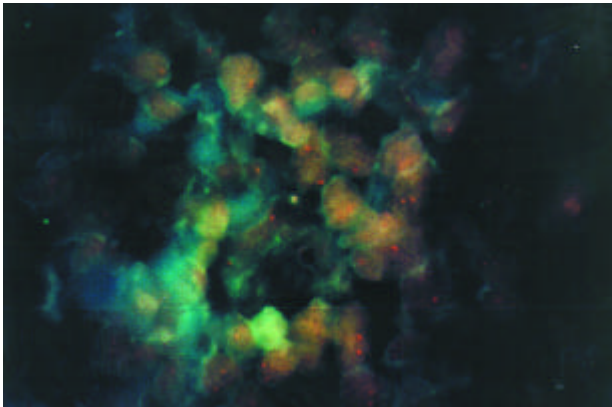
than eight gene copies). Signals were counted and the criteria for FISH anomalies was defined as previously explained.<sup>17</sup>

#### Immunohistochemistry

Immunohistochemistry was performed on the serial sections of the cases. 5 µm sections were deparaffinized in xylene, and rehydrated in descending grades (100%-70%) of ethanol. Deparaffinized slides were placed on the Ventana ES automated immunostainer and stained with the following protocol: c-erbB-2 monoclonal antibody (BioGenex CB11) for 30 min. The staining was completed with the 3-amino-3-ethylcarbazole (AEC) detection kit, and slides were counterstained with Mayer hematoxylin. Enzyme digestion was not used. Similar sections were also stained HER2/*neu* according to the instructions of the manufacturer and using the reagents included in the HerceptTest kit. The primary antibody included in the kit was polyclonal in a prediluted form. A known HER2/*neu* positive case of ductal carcinoma was used as the positive immunostaining control and two antibodies were used as a negative control. Tissue was processed in the same way except that the primary antibody was omitted.

#### Interpretation

Without knowledge of the results of the FISH tests and following the criteria recommended by DAKO for the HerceptTest all slides were reviewed by two pathologists. Overexpression of HER2/*neu* was defined as membranous staining in more than 10% of the neoplastic cells. Partial or



**Figure 1,2.** Amplification of Her-2/neu gene with a normal disomic complement for centromere 17 in each ductal carcinoma cell nuclei (DAPI X1000)

incomplete, weak to moderate, and moderate to strong membranous staining in more than 10% of the tumor cells were scored as 1 (negative), 2 (weak positive) and 3 (strong positive), respectively. The consensus was viewed as conclusive for indeterminate cases.

#### Statistical Analysis

Statistical analysis was based on two-sided Chi-Square test. The computations were performed using GraphPad InStat version 2.04 (GraphPad software USA). The statistical difference was considered significant if the p value was less than 0.05.

#### Results

The age of the patients at diagnosis ranged from 36 to 79 years (median, 60). Nine of the cases were stage T1, five of the cases were stage T2, one of the cases was T3. Histological Grading was performed by Scarff-Bloom-Richardson System and two cases were grade 1, one case was grade 3, the rest of all (12 cases) were grade 2. Two (2/15) of the

all analysed cases had lympho/vascular invasion and none of the cases had pagetoid spreading. One of the cases (1/15) had tumor positive excisional margin. Four (4/15) of the cases had lymph node metastasis (*Table 1*).

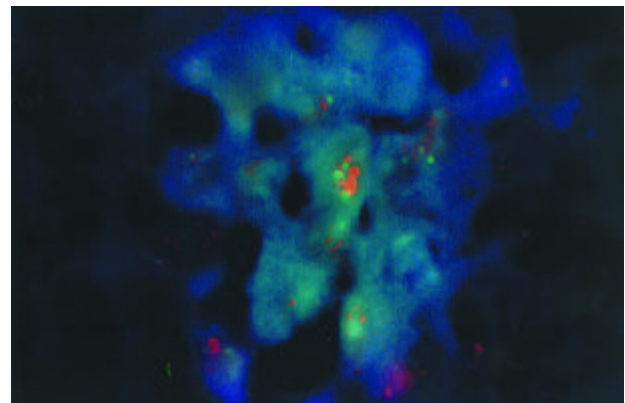
Direct 2-colour Her-2/neu chromosome 17 FISH analysis was performed on 15 cases. The use of chromosome 17 has important means in correcting Her-2/neu pseudoamplification due to chromosome 17 polysomy and the presence of the chromosome 17 probe also serves as an additional positive control for hybridization reaction.

Amplification was demonstrated in 27% (4/15) of the cases (*Figure 1,2,3*). The Her-2/neu-CEP17 ratio ranged from 2.1 to 11.7 (median 8.3)

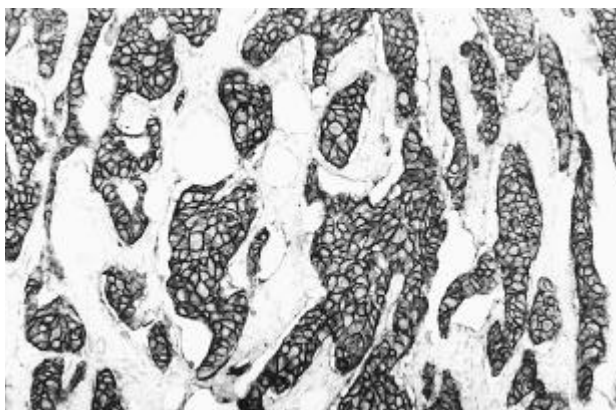
Her-2/neu protein overexpression was detected in 47% (7/15), and 80% (12/15) of the cases with CB11 and the HercepTest respectively (*Table 1, Figure 4*). Four cases that showed amplification of the Her-2/neu gene, demonstrated strong 3x immunostaining with HercepTest and all of these cases demonstrated either weak 2x or negative 1x immunohistochemical staining with CB11. From four amplified cases, one had lymph node metastasis and two other cases showed lympho/vascular invasion. We revealed statistically significant correlation between the oncogene amplification and oncoprotein overexpression ( $p < 0.05$ ), except for insignificant correlation between the HercepTest and CB11 overexpression. Statistically we found a significant correlation between the tumor stage and grade ( $p < 0.05$ ), but was not revealed correlation between oncoprotein expression or gene amplification ( $p < 0.05$ ).

#### Discussion

The Her-2/neu gene encodes a transmembrane protein with an extracellular growth factor receptor domain and an intracellular kinase domain.<sup>18</sup> Although some studies showed that genomic amplification of the Her-2/neu gene



**Figure 3.** Normal disomic complement for both HER-2/neu and centromere 17 as two orange and two green signals, respectively. (DAPI X1000)



**Figure 4.** Her-2/neu strong membranous immunoreactivity in ductal carcinomas of the breast (Hercept Test X40)

in patients with invasive breast carcinoma has been associated with a significant reduction in metastasis-free survival, other studies failed to confirm these findings.<sup>7</sup> The discordant findings in many of these studies might be related to technical variables associated with the methodologies used for detection of gene amplification or overexpression. Immunohistochemistry performance with different methods varies widely because of dilution artefacts by solid matrix blotting, antigenic alterations due to tissue fixation and extreme variability in the sensitivity of the available anti-erbB-2/ Her-2 antibodies.<sup>19, 20</sup> Sequence complementary DNA probes are used in FISH technique to quantify cellular Her-2/neu gene copy number and Her-2/neu gene copies relative to chromosome 17 number distinguishes the gene amplification from chromosomal aneuploidy.<sup>9</sup> FISH is a more objective and quantitative method compared to immunohistochemistry but FISH technique can also be complicated by nuclear truncation, which obscures enumeration of signals.

In this study we revealed a statistically significant association between gene amplification and protein overexpression with a concordance rate of 100 % for HerceptTest and CB11. The cases which demonstrated gene amplification showed strong 3x overexpression with HerceptTest or weak 2x and negative 1x immunostaining with CB11. This finding has concordance with the studies, which suggest that weak 2x overexpression is not specific to gene amplification.<sup>8,12,21</sup> The clinical significance of lower levels of immunoreactivity 2x and such discordance between genomic amplification and oncoprotein expression still remains uncertain.<sup>9,12,13,16</sup> In our study, among cases demonstrating weak 2x or negative with 1x protein expression, no gene amplification was detected in 8 of 12 cases with Hercept Test and BioGenex antibodies in 3 of 7 cases was not detected. Even one case that had strong 3x immunostaining with HerceptTest did not demonstrate gene amplification. True overexpression without gene

amplification has been described in 3 to 10% of breast carcinomas.<sup>13,16</sup> It is unclear whether they represent highly sensitive staining or a subset of cases that show overexpression without amplification. Ratcliffe et al,<sup>13</sup> demonstrated that amplification of the gene is an early event that might in some cases precede overexpression of the protein.<sup>13</sup> On the other hand, Tubbs et al,<sup>21</sup> demonstrated that discrepancies are not due to transcriptional regulation with overstatement of mRNA and Her-2/neu oncoprotein in the absence of genomic amplification, but rather false positive immunohistochemistry results.<sup>21</sup> In our study antibodies in oncoprotein overexpression demonstrated a statistically insignificant association. Five cases, which showed Her-2/neu oncoprotein overexpression with HerceptTest, did not demonstrate immunoreactivity with CB11.

In this study IHC and FISH methods display concordances but weak 2x immunoreactivity results with HerceptTest should be interpreted with caution in evaluating the results of IHC. We believe that combination of IHC and FISH methods enhances the evaluation of tumor genetics at both gene and protein level for the analysis of Her-2/neu in breast carcinoma.

#### Acknowledgement

Immunohistochemical study was performed at the Anatomic and Surgical Pathology Department of Università Di Bologna, Ospedale Bellaria. We are grateful to Professor Eusebi supporting immunohistochemistry.

#### References

- <sup>1</sup>Pettine S, Place R, Babu S, et al: Stereotactic breast biopsy accurate, minimally invasive, and cost effective. *Am J Surg* 171:474-476, 1996.
- <sup>2</sup>Wallace JE, Saylor C, McDowell NG, et al: The role of stereotactic biopsy assessment of nonpalpable breast lesions. *Am J Surg* 172:471-473, 1996.
- <sup>3</sup>Timothy WJ, Kallioji PS, Prioleau JE, et al: Do prognostic marker studies on core needle biopsy specimens of breast carcinoma accurately reflect the marker status of the tumor. *Mod Pathol* 11:259-264, 1998.
- <sup>4</sup>Bargmann CI, Hung MC, Weinberg RA: The neu oncogene encodes an epidermal growth factor receptor-related protein. *Nature* 319:226-230, 1986.
- <sup>5</sup>Slamon DJ, Clark GM, Wong SG, et al: Human breast cancer: correlation of relapse and survival with amplification of the HER-2/neu oncogene. *Science* 235:177-182, 1987.
- <sup>6</sup>Evans AJ, Pider SE, Ellis IO, et al: Correlations between the mammographic features of ductal carcinoma in situ (DCIS) and C-erbB-2 oncogene expression. Nottingham Breast Team: *Clin Radiol* 49:559-562, 1994.
- <sup>7</sup>Pauletti G, Godolphin W, Press MF, et al: Detection and quantitation of HER-2/neu gene amplification in human breast cancer archival material using fluorescence in situ hybridization. *Oncogene* 13:63-72, 1996.
- <sup>8</sup>Bankfalvi A, Simon R, Brandt B, et al: Comparative methodological analysis of erbB-2/HER-2 gene dosage, chromosomal copy number and protein overexpression in breast carcinoma tissues for diagnostic use. *Histopathol* 37:411-419, 2000.

- 9.<sup>2</sup>*Jimenez RE, Wallis T, Tabaszka P, et al:* Determination of Her-2/*neu* status in breast carcinoma: comparative analysis of immunohistochemistry and fluorescent in situ hybridization. *Mod Pathol* 13:37-45, 2000.
- 10.<sup>2</sup>*Press MF, Bernstein L, Thomas PA, et al:* HER-2/*neu* gene amplification characterized by fluorescence in situ hybridization: poor prognosis in node-negative breast carcinomas. *J Clin Oncol* 15:2894-2904, 1997.
- 11.<sup>2</sup>*Persons DL, Borelli KA, Hsu PH:* Quantitation of HER-2/*neu* and c-myc gene amplification in breast carcinoma using fluorescence in situ hybridization. *Mod Pathol* 10:720-727, 1997.
- 12.<sup>2</sup>*Hoang MP, Sahin AA, Ordonez NG, et al:* Her-2/*neu* gene amplification compared with Her-2/*neu* protein overexpression and interobserver reproducibility in invasive breast carcinoma. *Am J Clin Pathol* 113:852-859, 2000.
- 13.<sup>2</sup>*Ratcliffe N, Wells W, Wheeler K, et al:* The combination of in situ hybridization and immunohistochemical analysis: an evaluation of Her2/*neu* expression in paraffin-embedded breast carcinomas and adjacent normal appearing breast epithelium. *Mod Pathol* 10:1247-1252, 1997.
- 14.<sup>2</sup>*Scorilas A, Yotis J, Strvoulos K, et al:* c-erbB-2 overexpression may be used as an independent prognostic factor for breast cancer patients. *Anticancer Res* 15:1543-1648, 1995.
- 15.<sup>2</sup>*An H-X, Niederacher D, Dominik SI, et al:* Int-2 and c-erbB-2 gene amplification detected in 70 frozen human breast carcinomas by quantitative polymerase chain reaction. *Anticancer Res* 17:3133-3136, 1997.
- 16.<sup>2</sup>*Slamon DJ, Godolphin W, Jones LA, et al:* Studies of the HER-2/*neu* proto-oncogene in human breast and ovarian cancer. *Science* 244:707-712, 1989.
- 17.<sup>2</sup>*Hopman AHN, Ramaekers FCS, Raap AK, et al:* In situ hybridization as a tool to study numerical chromosome aberrations in solid bladder tumors. *Histochem* 89:307-316, 1988.
- 18.<sup>2</sup>*De Potter CR, Schelfout AM:* The neu-protein and breast cancer. *Virchows Arch* 426:107-115, 1995.
- 19.<sup>2</sup>*Ross JS, Fletcher JA:* The HER-2/*neu* oncogene in breast cancer: prognostic factor, predictive factor, and target for therapy. *Stem Cells* 16:413-428, 1998.
- 20.<sup>2</sup>*Press MF, Hung G, Godolphin W et al:* Sensitivity of HER-2/*neu* antibodies in archival tissue samples: potential source of error in immunohistochemical studies of oncogene expression. *Cancer Res* 54:2771-2777, 1994.
- 21.<sup>2</sup>*Tubbs RR, Pettay JD, Roche PC, et al:* Discrepancies in clinical laboratory testing of eligibility for trastuzumab therapy: apparent immunohistochemical false positives do not get the message. *J Clin Oncol* 15:2714-2721, 2001.