

ARTICLE

Expression of Bcl-2 and Bax In Chewing Tobacco-Induced Oral Cancers and Oral Lesions from India

Tanuja TENI,¹ Sagar PAWAR,¹ Vikram SANGHVI,² Dhananjaya SARANATH^{1*}

¹Laboratory of Cancer Genes, Cancer Research Institute, Tata Memorial Centre; ²Department of Surgery, Tata Memorial Hospital, Tata Memorial Centre, Parel, Mumbai, India

Deregulation of oncogenes and tumor suppressor genes involved in apoptosis has been associated with tumor development and progression. To investigate the involvement of apoptosis regulating proteins in oral cancer in Indian patients, primarily associated with chewing tobacco habits, immunohistochemical expression of bcl-2 and bax was examined in 63 oral squamous cell carcinomas, and 31 putative premalignant lesions. Our studies revealed overexpression of tumor specific cytoplasmic bcl-2 in 56% and bax in 43% oral cancers. The oral cancers in the Indian patients are preceded by premalignant oral lesions; hence oral lesions were examined for bcl-2 and bax expression. We observed aberrant expression of bcl-2 in 16% oral lesions comprising leukoplakias and SMF and bax in 55% oral lesions. We have already reported, p53 expression in these oral cancers and lesions. It was noteworthy that 30% oral cancers demonstrated a p53+bcl2+ pattern, and 14% samples exhibited p53+bcl2+bax+ pattern. However, none of the oral lesions showed concurrent deregulation of

p53 and bcl-2 or all the three genes. Interestingly 45% oral lesions were p53-bax+ as compared to 18% oral cancers; while 39% oral lesions were bcl2-bax+ as compared to 14% oral cancers, indicating overexpression of bax in oral lesions, in the absence of p53 and bcl-2 proteins. Significant correlation was observed between positive nodal status and bcl2+ (p=0.047) and p53+bcl-2+ (p=0.01) in oral cancers. Kaplan Meier survival analysis showed significantly (p=0.059) higher survival in patients with p53- oral tumors than with p53+ tumors. Our studies thus indicate frequent overexpression of apoptosis regulators bcl-2, bax and p53 proteins in oral cancers, and a subset of oral lesions, representing early events in oral carcinogenesis. The aberrant bcl-2 expression and loss of p53 function observed, may play an important role in the tumorigenesis of oral cancers by allowing escape from apoptosis and enabling additional genetic alterations to accrue. (Pathology Oncology Research Vol 8, No 2, 109–114, 2002)

Keywords: bcl-2, bax, p53, oral cancer, oral lesions, immunohistochemistry

Introduction

Significant geographic variation is noted in the incidence of oral cancer, with high rates reported for the Indian subcontinent and parts of Asia (male incidence rates in excess of 10 per 100,000 per annum).¹ In India, cancer of the oral cavity (ICD-9, 141, 143–145) is one of the five leading sites of cancer in either sex. The age standardized

incidence rates (ASR) vary from 6.2 per 100,000 in Bangalore to 16.1 per 100,000 in Bhopal among urban males, and from 3.5 in Delhi to 7.8 per 100,000 in Chennai among urban females.² On the basis of the cancer registry data, it is estimated that annually 75,000–80,000 new oral cancer cases develop in India.²

In India, the majority of oral cancers are unequivocally associated with tobacco-chewing habits, and usually preceded by premalignant lesions - most often a persistent leukoplakia or oral submucous fibrosis (SMF). The oral leukoplakias and SMFs have been reported to show an increased risk of conversion to malignant transformation varying from 0.13% to 6%, and the risk further increased to 14% or higher in dysplastic lesions.^{3,4} Our laboratory has been investigating the molecular basis of human oral

Received: Febr 7, 2002; *accepted:* May 22, 2002

Correspondence: Dr. Dhananjaya SARANATH, Head, Department of Molecular Medicine and Biology, Deputy Director – Research, Jaslok Hospital and Research Centre, 15, Dr.G.Deshmukh Marg, Mumbai – 400026, India; Tel: + 91-22-4933333, Fax: + 91-22-4950508, e-mail: dsaranath@jaslokhospital.net

cancers associated with tobacco chewing habits. We have earlier demonstrated tumor associated activation of oncogenes via amplification, point mutation and deletion of *myc/ras/erbB1* genes.⁵⁻⁹ Besides, we have also analysed microsatellite alterations on chromosome 3, 9, and 17 in oral cancer tissues and demonstrated a high incidence of genetic alterations in the chromosomal regions of 3p 12-14¹⁰ and 9p 21-23.¹¹

Our group has previously demonstrated the inactivation of p53 tumor suppressor gene via point mutations, overexpression and degradation due to HPV 16/18 infection and of allelic loss in oral cancer tissues.^{12,13} The p53 gene not only participates in cell proliferation control, but also plays a role in elimination of cells with DNA damage by induction of apoptosis.¹⁴ Studies indicate that the p53 gene interacts inversely with the *bcl2* gene and positively upregulates the *bax* gene in the regulation of apoptosis.¹⁵ The *bcl2* gene, encoding a 25 kd protein located both in the inner mitochondrial membrane and in cell cytosol, has been shown to prolong cell survival by inhibiting apoptosis and may promote tumor development.¹⁶ An overexpression of the *bcl2* gene has been reported in haematopoietic malignancies and several solid tumors including oral cancers.¹⁶ Besides, in many tumors, overexpression of *bcl2* has been shown to confer cytotoxic drug resistance in response to various chemotherapeutic agents, presumably due to its ability to inhibit chemotherapy induced apoptosis.¹⁶

The clinicopathological and molecular pathological profile of the Indian oral cancers show significant differences from the oral cancers in several developed countries of the world, including USA, UK, France, Japan, associated with tobacco smoking with/without alcohol consumption.⁹ Given the presumed functions of p53/*bax/bcl2* proteins as effectors or repressors in the common molecular pathway of apoptosis, in the present study we have examined the expression of *bcl-2* and *bax* in oral cancers and putative premalignant lesions.

Materials and Methods

Patients with Oral Cancer

Sixty-three previously untreated patients with oral squamous cell carcinomas, 45 males and 18 females ranging in age from 22–78 years (median age 45 years) were studied for *bcl-2* and *bax* over-expression. All the patients were habitual tobacco chewers of a minimum duration of 10 years. The primary sites of the cancer were as follows: buccal mucosa, 30 cases; alveolus, 20 cases; tongue 11 cases; lip 1 case; and floor of mouth 1 case. The majority of the patients (n = 59) were diagnosed in advanced stages III/IV, with only four patients in stages I/II, according to TNM classification. Histopathologically, the oral cancers were categorised as well differentiated – 17 cases, moderately differentiated – 29 cases and poorly differentiated –

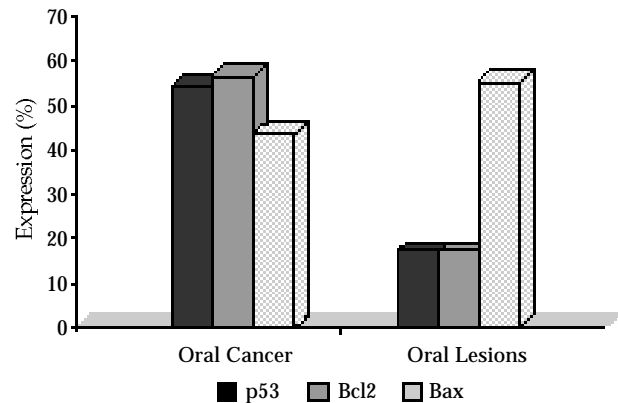


Figure 1. Expression of *Bcl-2*, *bax* and *p53* in oral cancers and oral lesions

17 cases. Forty cases were node positive, while 23 cases were node negative. The size of the tumor varied from 4 cm (35 patients) to > 4 cm (28 patients). Tumor samples were collected at the time of surgery from the primary site of the tumor after informed consent was obtained from patients attending Tata Memorial Hospital, Mumbai.

Patients with oral lesions

Thirty one putative premalignant lesions constituting 14 leukoplakias with mild hyperplasia and minimal dysplasia (11 males and three females), 28–65 years of age (median age, 40 years), and 17 oral submucous fibrosis (SMF) (14 males and 3 females), 25–70 years of age were studied for *bcl-2* and *bax* protein expression. Majority of the individuals were tobacco chewers for a minimum period of 5 years.

Immunohistochemical staining

Formalin-fixed, paraffin-embedded oral cancer tissues or oral lesions were used for *bcl-2* and *bax* protein detection. Sections (5 μ m) were mounted on silane (3-aminopropyl triethoxy silane; Sigma, St.Louis, USA)-coated slides, and a slide from each sample was stained with haematoxylin and eosin. After deparaffinization with xylene and rehydration through ethanol series, endogenous peroxidase activity in the tissue sections was blocked by treatment for 30 min with 0.6% hydrogen peroxide in methanol. Microwave antigen retrieval was carried out by placing the slides in 10 mM sodium-citrate buffer, pH 6.0, in a microwave oven at 800 W for 10 min. Nonspecific binding of the antibody was blocked by diluted (1:30) horse serum for 30 min. Immunostaining was carried out by use of avidin biotin-peroxidase enzyme complex (ABC Kit, Vector Laboratories, Denmark) with *bax* specific polyclonal antibody (Pharmingen), and *bcl2* specific monoclonal antibody clone 124 (Dako, Denmark). The sections were visualised by adding the substrate 3-

3'diaminobenzidine (0.05% DAB) and 0.1% H₂O₂ in phosphate-buffered saline (PBS) for 10 min and counterstained with Mayers hematoxylin. The bcl-2 positive (tonsil tissue) and negative (replaced clone 124 with PBS) controls were included with each set of immunohistochemical analysis.

A minimum of 1000 cells from the positive stained area were selected and scored. Bcl-2 and bax expression was estimated semi-quantitatively as percent positive cells with 10–30% cancer cells stained = 1+; 31–50% cancer cells stained = 2+; >50% cancer cells stained = 3+; and <10% tumor cells stained considered negative.

Statistical analysis

A Chi-square test (Yates' correction factor applied) was used for evaluation of correlation of gene expression with various clinicopathological features in oral cancer and pre-malignant oral lesions – leukoplakias and SMF. Survival analysis was carried out using the Kaplan Meier method. All p values reported are two-sided. The significance level chosen was p=0.05.

Results

The expression of bcl-2, and bax in oral cancer and oral lesions is summarized in *Figure 1*. Our studies revealed over-expression of bcl-2 in the cytoplasm of epithelial cells in 35/63 (56%) oral cancers, and 6/31 (16%) oral lesions. Within the tumor tissue, lymphocytes were used as internal positive controls and showed cytoplasmic staining for bcl-2 protein. In oral cancers, bcl-2 overexpression showed significant correlation with nodal status (p=0.047), and well and moderate differentiation (p=0.049). In well and moderately differentiated tumors, bcl-2 staining was found to be generally restricted to tumor cells within the centre of tumor islands (*Figure 2a*). Basal cells expressed low level or absence of bcl-2 protein (*Figure 2b*). In poorly differentiated tumors, diffuse cytoplasmic staining for bcl-2 was seen throughout the tumor cell population. Bcl-2 expression was detected in superficial layers of oral lesions as shown for SMF (*Figure 2c*) and leukoplakias (*Figure 2d*). In 35/63 oral cancers that were bcl-2 positive, 23% cases were 3+, 26% cases were 2+ and 51% cases were 1+; while in 6/31 oral lesions that were bcl-2 positive, all the six cases were 1+.

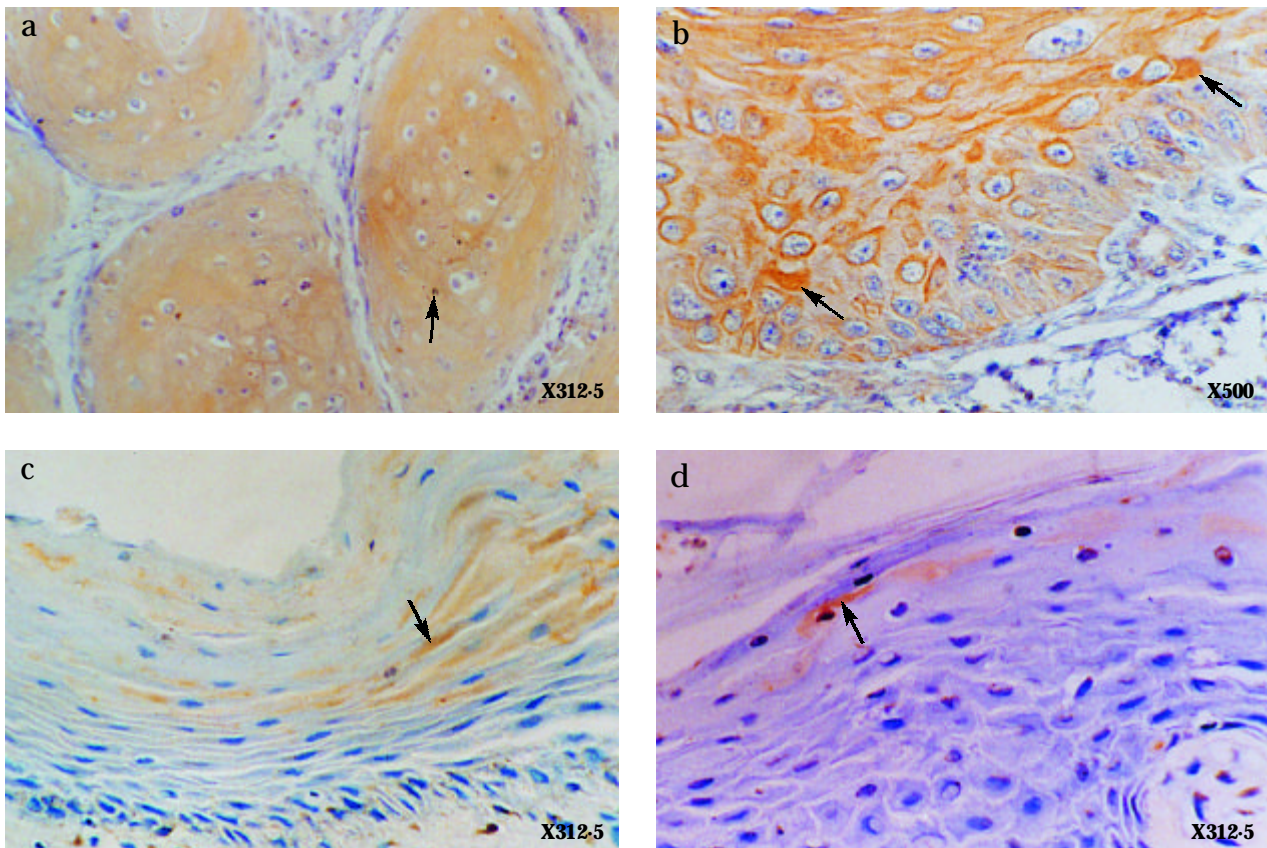


Figure 2. A composite picture of bcl-2 expression in oral cancers and oral lesions. (a) A well differentiated oral squamous cell carcinoma showing high bcl2 expression in the cells of tumor islands. (b) A moderately differentiated oral carcinoma showing Bcl2 expression in the tumor cells. (c) Submucous fibrosis expressing Bcl2 in the superficial layer of epithelia. (d) Leukoplakia illustrating bcl2 immunoreactivity.

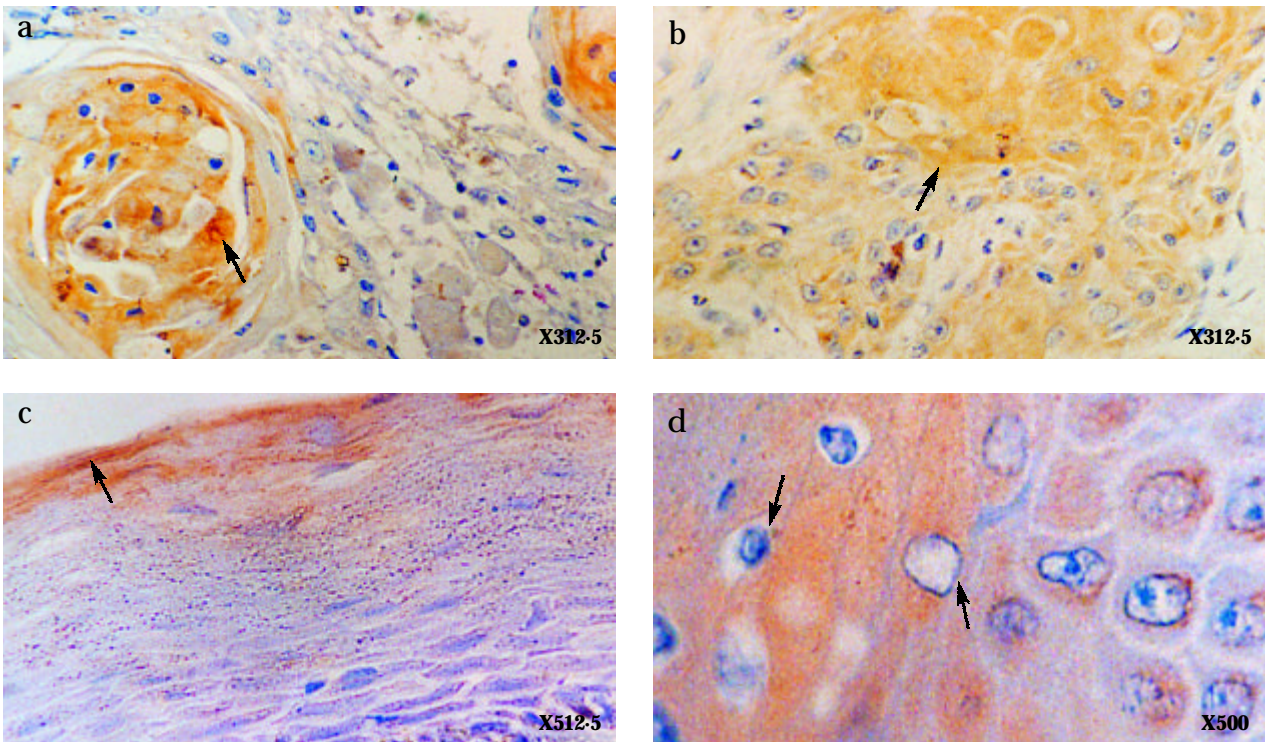


Figure 3. A composite picture of bax expression in oral cancers and oral lesions. (a) A well differentiated oral squamous cell carcinoma showing high bax expression in the centre of tumor islands. (b) A moderately differentiated oral carcinoma illustrating bax expression in the tumor cells. (c) Submucous fibrosis showing bax expression in the superficial layers of epithelia. (d) Leukoplakia illustrating bax immunoreactivity.

Bax expression was observed in 27/63 (43%) oral cancers (Figure 3b), and oral lesions in 17/31 (55%) samples. Diffuse staining for bax was prominent within the center of tumor islands (Figure 3a), in well and moderately differentiated tumors. In oral lesions (Figure 3c,d), bax was predominantly present in the squamous epithelial cells of superficial layers. In 27/63 oral cancers that were bax positive, 26% cases were 3+, 33% cases were 2+ and 41% cases were 1+. In 17/31 oral lesions that were bax positive, 6% cases were 3+, 65% cases were 2+, and 29% were 1+.

The above samples have been analysed for deregulated expression of p53 and demonstrated in cellular nuclei of 34/63 (54%) tumors and 5/14 (36%) leukoplakias as reported earlier.¹³ In the seventeen SMF, p53 was not expressed, a consistent feature in our SMFs. In majority of well and moderately differentiated tumors, p53 immunoreactivity was found to be restricted to the basal and parabasal proliferative compartment of tumor islands. Besides, p53 inactivation showed significant association with stage III and IV ($p=0.040$).

The combined expression patterns of p53 and bcl-2, bcl-2 and bax, and p53 and bax in oral cancer and oral lesions were analysed. It is noteworthy that 30% of oral cancers demonstrated p53+bcl-2+ pattern and 14% samples exhibited p53+bcl-2+bax+ pattern. However, none of the oral

lesions showed concurrent deregulation of p53 and bcl-2 or all the three genes. Interestingly, 45% oral lesions were p53-bax+ as compared to 18% oral cancers; while 39% SMF were bcl-2-bax+ as compared to 14% oral cancers, indicating overexpression of bax in oral lesions, in the absence of p53 and bcl-2 proteins. Interestingly, 79% oral cancers were either p53+/bcl-2+/p53+bcl-2+, while 36% of oral lesions exhibited the same pattern. Significant correlations were observed between positive nodal status and p53+bcl-2+ tumors ($p=0.01$). Besides, Kaplan Meier survival analysis showed significantly ($p=0.059$) higher survival in patients with p53- oral tumors, than with p53+ tumors. However, no significant difference in survival was observed in relation to bcl-2 or bax expression (Figure 4).

Discussion

The present study demonstrates frequent (43%-56%) over-expression of apoptosis regulating proteins bcl-2 and bax, as well as p53, in the tobacco chewing associated Indian oral cancers. In addition, aberrant bcl-2 and p53 expression was demonstrated in a subset (16%) of oral lesions, representing early events in oral tumorigenesis. Interestingly, alterations in both p53 and bcl-2, or in all three proteins - p53, bcl-2 and bax, were observed in oral

tumors (30%; 14% respectively); but were totally absent in oral lesions, thus indicating a critical role for aberrant bcl-2 and p53 in the development of oral cancers. Further, bcl-2 expression in oral cancers, either singly or with deregulated p53, correlated significantly with positive nodal status ($p=0.047$), indicating association with advanced or

aggressive disease. Besides, we observed, bcl-2 and p53 aberrations associated with moderately differentiated tumors ($p=0.049$, $p=0.054$). However, Jordan et al¹⁷ have demonstrated association of bcl-2 expression with poorly differentiated oral carcinomas, as also demonstrated in esophageal and thyroid carcinomas.¹⁸ The differentiated cells within the tumor nests/islands were found to express high levels of bcl-2 as compared to peripheral basal cells. In normal oral epithelia, bcl-2 protein is restricted to the basal layer, and may participate in regulation of the terminal differentiation of keratinocytes, by protecting stem cells from apoptosis.¹⁸ Studies also indicate that in dysplastic epithelia and in histologically normal epithelia distant to tumors, the up-regulated bcl-2 protein is exhibited in all layers of the epithelia.¹⁹

Over-expression of bcl-2 has been reported in several tumors including breast, thyroid, lung and skin carcinomas¹⁸. In oral carcinomas, overexpression of bcl-2 from 7% to 60% has been reported from developed countries,²⁰⁻²³ while Ravi et al,²⁴ and Kannan et al²⁵ reported 100% and 23% bcl-2 expression respectively, in oral cancers from Southern India. Our studies from Western India, with differing life styles and habits from the group in South India, demonstrates bcl-2 in 56%, bax in 43% and p53 expression in 54% oral cancers; whereas in pre-cancerous lesions 16% cases showed bcl-2, 55% demonstrated bax, and 16% exhibited p53. McAlinden et al²⁶ have reported absence of bcl-2 expression in oral premalignant lesions. The differences in bcl-2 and bax expression, from the various studies may reflect subtle inherent differences in upstream genetic events between the different population groups, as also the environmental differences.

In our studies, bax was found to be associated with moderately differentiated tumors unlike that reported by Jordan et al.¹⁷ Our study demonstrates occurrence of both bcl2 and bax in the central cells of tumor islands and in the superficial epithelial layers of oral lesions, implying the probable heterodimerization of bcl-2/bax in the tissues. In our studies, bax distribution showed a pattern similar to that reported in normal epithelium. The high expression of bax in SMF, in the absence of p53 indicated involvement of an alternative mechanism of bax up-regulation in SMF.

These studies thus indicate that alterations in bcl-2, bax and p53 may play an important role in the development of Indian oral squamous cell carcinomas, probably by allowing escape from apoptosis. In addition, overexpression of the proteins in premalignant lesions, suggests a role in early stages of oral carcinogenesis.

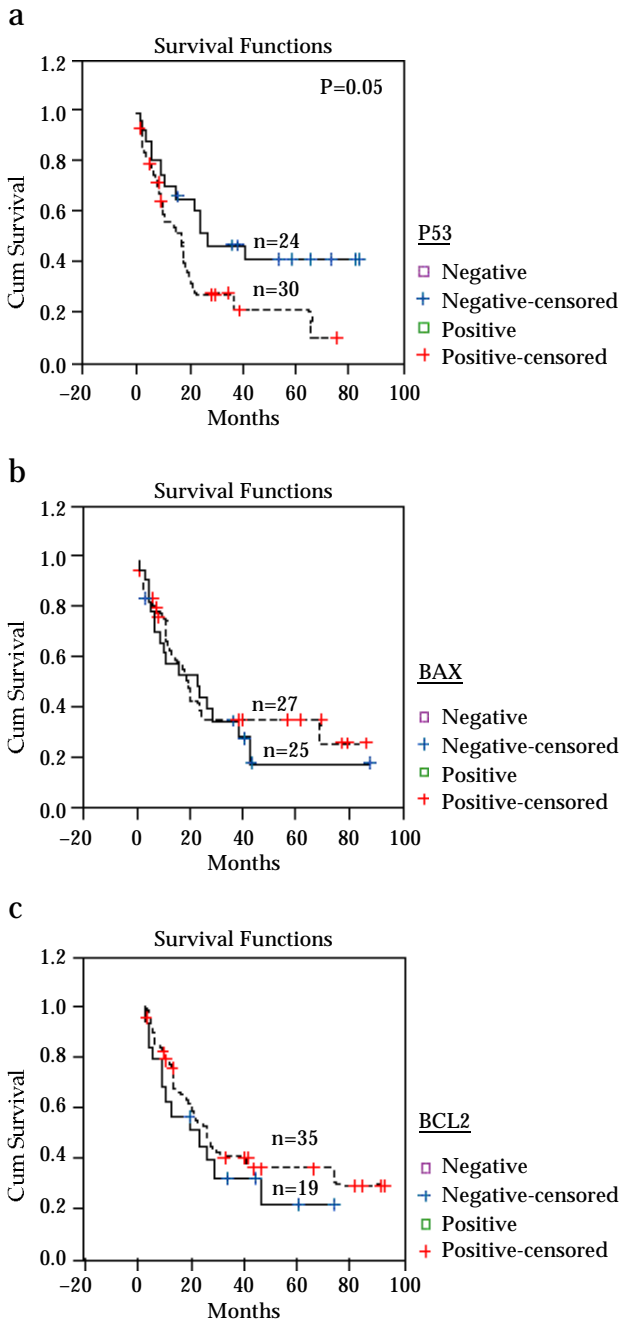


Figure 4. Kaplan Meier curves for overall survival. (a) In relation to p53 status – p53 positive (dashed line) and p53 negative (solid line) ($p=0.05$). (b) In relation to bax status – bax positive (dashed line) and bax negative (solid line). (c) In relation to bcl-2 status – bcl-2 positive (dashed line) and bcl-2 negative (solid line)

Acknowledgement

The help provided by Mrs. Sadhana Kannan, Biostatistician, Cancer Research Institute, Mumbai, in statistical analysis of the data, is gratefully acknowledged.

References

1. Moore SR, Johnson NW, Pierce AM, Wilson DF: The epidemiology of mouth cancer: a review of global incidence. *Oral Diseases* 6:65-74, 2000.
2. National Cancer Registry Programme: Consolidated Report of the Population Based Cancer Registries : 1990-1996, Incidence and Distribution of Cancer under the ICMR, New Delhi, August 2001.
3. Gupta PC, Bhonsle RB, Murti PR, et al: An epidemiological assessment of cancer risk of oral precancerous lesions in India with special reference to nodular leukoplakia. *Cancer* 63:2247-2251, 1989.
4. Tradati N, Grigolat R, Calabrasc L, et al: Oral leukoplakia to treat or not? *Oral Oncol* 33:317- 321, 1997.
5. Saranath D, Panchal RG, Nair R, et al: Oncogene amplification in squamous cell carcinoma of the oral cavity. *Jpn J Cancer* 80:430-437, 1989.
6. Saranath D, Panchal RG, Nair R, et al: Amplification and overexpression of epidermal growth factor receptor in human oropharyngeal cancer. *Eur J Cancer B Oral Oncol.* 28:139-143, 1992.
7. Saranath D, Chang SE, Bhoite LT, et al: High frequency mutation in codon 12 and 61 of H-ras oncogene in chewing tobacco related human oral carcinomas in India. *Br J Cancer* 63:573-578, 1991.
8. Saranath D, Bhoite LT, Mehta AR, et al: Loss of allelic heterozygosity at the Harvey locus in human oral carcinomas. *J Cancer Res Clin Oncol.* 117:483-488, 1991.
9. Saranath D, Bhoite LT and Deo MG: Molecular lesions in human oral cancer: the Indian scene. *Eur J Cancer Oral Oncol.* 29:107-112, 1993.
10. Tandle A and Saranath D: Genetic alterations on chromosome 3, p53 tumor suppressor gene and telomerase activity in oral cancers from India. *Asian Pacific Journal of Cancer Prevention, Vol. I APCC Supplement* 219-225, 2000.
11. Mahale A and Saranath D: Microsatellite alterations on chromosome 9 in chewing tobacco -induced oral cell carcinomas from India. *Oral Oncol* 36:199-206, 2000.
12. Saranath D, Tandle AT and Deo MG: Loss of p53 gene as a biomarker of high risk oral leukoplakia. *Indian J Biochem Biophys* 34:266-273, 1997.
13. Saranath D, Tandle AT, Teni TR, et al: p53 inactivation in chewing tobacco-induced oral cancers and leukoplakias from India. *Oral Oncol.* 35:242-250, 1999.
14. Field JK, Spandidos DA and Stell PM: Overexpression of the p53 gene in head and neck cancer, linked with heavy smoking and drinking. *Lancet* 339:502-503, 1992.
15. Miyashita T, Krajewski S, Krajewska M, et al: Tumor suppressor p53 is a regulator of bcl2 and bax expression in vitro and in vivo. *Oncogene* 9:1799 -1805, 1994.
16. Wang Y, Szekely L, Okan J, Klien G et al: Wild type p53 triggered apoptosis is inhibited by bcl2 in v-myc induced T-cell lymphoma lines. *Oncogene* 8:3427-3431, 1993.
17. Pollina L, Pacini F, Fontanini G et al: Bcl2, p53 and proliferating cell nuclear antigen expression is related to the degree of differentiation in thyroid carcinomas. *Br J Cancer* 73:139-143, 1996.
18. Qi-Lung, Abel P, Foster CB, et al: Bcl-2: Role in epithelial differentiation and oncogenesis. *Human Pathol.* 27:102-109, 1996.
19. Jordan RCK, Catzavelos GC, Barrett AW et al: Differential expression of bcl2 and bax in squamous cell carcinomas of the oral cavity. *Oral Oncol.* 32B:394-400, 1996.
20. Stoll C, Baretton G, Abrens C, et al: Prognostic significance of apoptosis and associated factors in oral squamous cell carcinoma. *Virchows Arch* 436:102-108, 2000.
21. Birchall MA, Schock E, Harmon BV et al: Apoptosis, Mitosis, PCNA and bcl2 in normal, leukoplakic and malignant epithelia of the human oral cavity: prospective, in-vivo study. *Oral Oncol* 3:419-425, 1997.
22. Pena J, Thompson CB, Recant W et al: Bcl-x_L and Bcl2 expression in squamous cell carcinoma of head and neck. *Cancer* 85:164-170, 1999.
23. Yao L, Iwai M and Furuta I: Correlation of bcl2 and p53 expression with the clinico pathological features in tongue squamous cell carcinomas. *Oral Oncol.* 35:56-62, 1999.
24. Ravi D, Ramadas K, Mathew BS, et al: De novo programmed cell death in oral cancer. *Histopathol.* 14:241-249, 1999.
25. Kannan K, Lakshmi Latha PN and Shanmugan G: Expression of bcl2 oncoprotein in Indian oral squamous cell carcinomas. *Oral Oncol* 34:373-377, 1998.
26. McAlinden RL, Maxwell P, Napiet S, et al: Bcl-2 expression in sequential biopsies of potentially malignant oral mucosal lesions assessed by immunocytochemistry. *Oral Diseases* 6:318-326, 2000.