

CASE REPORT**Combined Occurrence of Prostate Carcinoma and Malacoplakia**Dénes L RÉPÁSSY,¹ András IVÁNYI,² Sándor CSATA,¹ György TAMÁS¹¹Department Urology, and ²Department Pathology, Saint Stephen Hospital, Budapest, Hungary

This is a case of a 56-year-old male patient suffering from a combination of prostate carcinoma and malacoplakia. A 56-year-old male patient was admitted in our Department because ischuria due to the enlargement of the prostate. Perineal needle biopsy was done resulting carcinoma of prostatae. Radical prostatectomy was performed. Histology proved carcinoma and a great part of the enlarged

prostate consisted of malacoplakia. Questions related to the morphology, tissue structure as well as diagnosis are briefly surveyed. This is the first report on the rarely occurring combination of prostate carcinoma and malacoplakia treated by radical retropubic prostatectomy. (Pathology Oncology Research Vol 8, No 3, 202–203, 2002)

Keywords: prostate carcinoma, malacoplakia, radical prostatectomy

Introduction

Malacoplakia is a very rarely occurring disease of unknown aetiology, inflammatory in character.¹ Its most frequent location is in the urinary tract, but it may also rarely occur in the testicles, lungs and the alimentary tract. It is a tumour-like, sometimes polypoid formation of soft and loose consistency. The designation „malacoplakia“ means „soft spot“. In 1902, Michaelis and Gutmann were the first authors whose attention was drawn to this rare „tumor“ of the bladder mucosa, the cells of which contained typical cytoplasmic inclusions.² The formation was named after these authors, then later the designation malacoplakia was introduced by Hansemann in 1903.³ At that time, malacoplakia was thought to be a tumour. In general, its incidence is very low and it occurs extremely rarely in the prostate.^{4,5,6}

Case Report

A 56-year-old male patient suffered from acute prostatitis 6 years prior to his admission to our Department. An indwelling catheter was fixed in his urethra for a period of a week. After removing the catheter he began to urinate spontaneously without any disturbance. The process

healed. A week before his present admission ischuria appeared, so a catheter was fixed again. Rectal palpation showed the prostate to be as large as a green walnut, more compact than muscular. Malignancy was considered, and rectal ultrasonography (US) proved this assumption. Its mostly heterogeneous structure resulted in hypoechogenicity. Histology – needle biopsy – was indicative of eosinophilic histiocytes in large areas (malacoplakia) and adenocarcinoma in a small area. Changes suggestive of metastases were not shown by bone scintigraphy.

Retropubic radical prostatectomy was performed. A moderate enlargement of the lymph nodes was seen in the course of pelvic lymphadenectomy, but only reactive inflammation was shown by histology. After an undisturbed postoperative period, the patient's urination was continuous, without retention, but erectile dysfunction developed. Histological examination of the surgical specimen proved the presence of malacoplakia in the major part of the prostate (*Figure 1*) and the presence of carcinoma in small foci (*Figure 2*). The PSA value increased moderately preoperatively, falling to 0.3 after surgery. The postoperative follow-up did not show increasing PSA. No clinical progress has been observed since then.

Discussion

About 20 cases of malacoplakia affecting the prostate have been reported in the world literature. In the prostate, malacoplakia is a peculiar form of prostatitis, which may

Received: Nov 16, 2001; *accepted:* July 15, 2002

Correspondence: Dénes László RÉPÁSSY, MD, Department Urology, Saint Stephen Hospital, Nagyvárad tér 1, H-1096 Budapest, Hungary

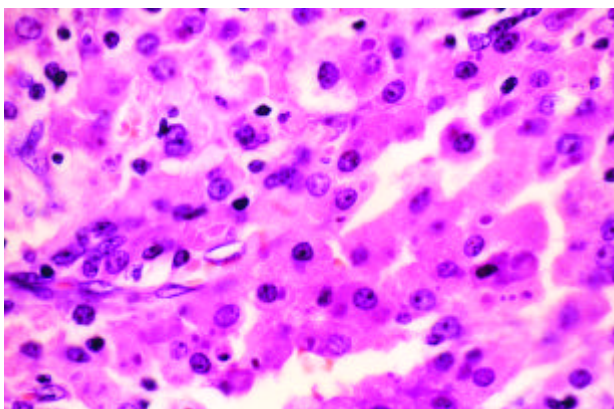


Figure 1. Prostatic adenocarcinoma. HEEx100

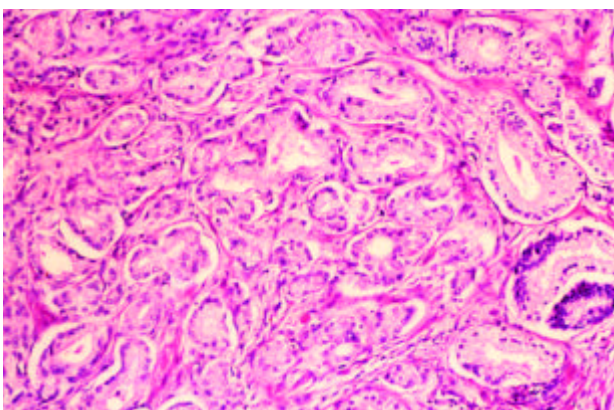


Figure 2. Typical cells of prostatic malakoplakia. HEEx140

lead to the enlargement of the prostate. Due to the obstruction of the lower part of the urinary tract, and to the irritation, the clinical symptoms resemble those of BPH. The normal histological structure of the prostate practically disappears and a tissue consisting of large histiocytes develops instead. The cells – Hasemann's cells – are eosinophilic with fine granulation, some of them with typical cytoplasmic inclusions (Michaelis-Gutmann body). The prostate is characterized by a uniformly compact structure; it can be differentiated from adenoma when palpated. Malakoplakia and carcinoma of the prostate occurs together extremely rarely.^{7,8,9,10}

The aetiology and pathogenesis of malakoplakia are unknown. The fact that malakoplakia induces the same

picture in different organs supports the assumption of a common pathogenesis, independent of location. Certain authors have attributed causative role to tuberculosis, sarcoidosis or other malignancies; others prefer the role of chronic infection (*Escherichia coli*).⁴ In patients with immunodeficiency, defective histiocytic phagocytosis and consequent insufficient processing of the phagocytosed material may be the focus of the pathogenesis. Different phagocytic factors may co-operate in the process.⁴

The characteristic histological appearance makes histological examination necessary. Differentiation between prostatitis and prostatic carcinoma is of special importance.

Broad-scale antibiotic and anti-inflammatory treatment is central to therapy.

The present case is of interest because clinical examinations raised the suspicion of prostatic carcinoma and the assumption was proved by needle biopsy. However, palpation and ultrasonographs were suggestive of malakoplakia. Radical prostatectomy was indicated by the presence of carcinoma, which - on this rare occasion - was combined with malakoplakia.

References

- ^{1,2}Long JP Jr, Althausen AF: Malakoplakia: a 25-year experience with a review of the literature. *J Urol* 14:1328-1331, 1989
- ²Michaelis L, Gutmann C: Über einschliesse in Blasentumoren. *Ztschr Klin Med* 47:20-215, 1902
- ³Von Hansemann D: Über Malakoplakie der Harnblase. *Wirsch Arch Path Anat* 173:302-308, 1903
- ⁴Sarma HN, Ramesh K, al Fituri O, et al: Malakoplakia of the prostate gland. Report of two cases and review of the literature. *Scand J Urol Nephrol* 30:155-157, 1996
- ⁵Suzuki Z., Kubota Y, Sasagawa I, et al: Malakoplakia of the prostate. *Int Urol Nephrol* 27:551-555, 1995
- ⁶Koga S, Arakaki Y, Matsouka M, Ohyama C: Malakoplakia of prostate. *Urology* 27:160-161, 1986
- ^{7,2}Thrasher JB, Donatucci CF: Malakoplakia and carcinoma of the prostate. *Br J Urol* 73:111-112, 1994
- ⁸Liu S, Christmas TJ, Kirby RS: Malakoplakia and carcinoma of the prostate. *Br J Urol* 72:120-121, 1993
- ⁹Sujka SK, Malin BT, Asirwatham JE: Prostatic malakoplakia associated with prostatic adenocarcinoma and multiple prostatic abscesses. *Urology* 34:159-161, 1989
- ¹⁰Chantelois AE, Parker SH, Sims JE, Horne DW: Malakoplakia of the prostate sonographically mimicking carcinoma. *Radiology* 177:193-195, 1990