

CASE REPORT

Calcium Oxalate Precipitates in a Renomedullary Interstitial Cell Tumor

Irene PECORELLA, Sebastian B LUCAS,¹ Antonio CIARDI, Lorenzo MEMEO, Robert F MILLER²

Dipartimento di Medicina Sperimentale e Patologia, Università degli Studi "La Sapienza", ROMA, Italy,

¹Department of Histopathology – Guy's Kings and St Thomas's School of Medicine, St Thomas's Hospital, London, UK,

²Department of Sexually Transmitted Diseases – Windeyer Institute of Medical Sciences, Royal Free and University College Medical School and Camden and Islington Community Health Services Trust, London

We report a case of calcium oxalate deposition in a renomedullary interstitial cell tumor (RICT) in a patient dying of full-blown AIDS. The precipitates showed birefringence using a partially polarised light and were stained black in Yasue's silver nitrate-rubeanic acid method. The combination of cal-

cium oxalosis and RICT has not been reported before and might possibly be due to systemic biochemical alterations of the glycosaminoglycans as a result of profound metabolic disturbances in AIDS patients. (Pathology Oncology Research Vol 9, No 1, 47–48, 2003)

Keywords: calcium oxalate, kidney, renomedullary interstitial cell tumor

Introduction

Precipitation of calcium oxalate crystals in different types of human tissues may occur as a result of hereditary (primary) or acquired (secondary) hyperoxalaemia and in altered tissues without a concomitant hyperoxalaemia (dystrophic). In the kidneys, crystals of oxalate have been identified in cases of hereditary oxalosis, glycol nephrosis and chronic renal disease with uraemia, but also in patients with no evidence of renal or systemic disease.¹ The calcific precipitates are found chiefly in tubular lumina, sometimes in interstitial tissue, and only rarely within glomeruli.¹ Here we report a case of calcium oxalate deposition in a renomedullary interstitial cell tumor (RICT) in an AIDS patient.

Case Report

The RICT was detected microscopically in a 29-year-old homosexual patient who had died of bacterial bronchopneumonia and HIV encephalitis. The tumor was composed of elongated or oval stromal cells with indis-

tinct cytoplasmic borders and separated by dense collagen. In the central portion of the lesion, an eosinophilic, acellular area appeared to contain a myriad of plate-like or diamond-shaped colourless crystals, which showed birefringence using a partially polarised light (*Figure 1*). The precipitates were stained black in Yasue's silver nitrate-rubeanic acid method. No other deposits were observed in multiple samples of the patient's kidneys or in several other tissue samples.

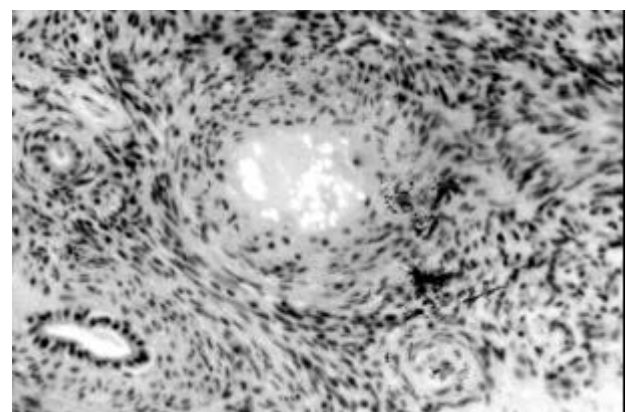


Figure 1. Birefringent calcium oxalate crystals lay in an acellular eosinophilic matrix in the central portion of the renomedullary interstitial cell tumor (Haematoxylin-eosin and partially polarised light; 100x)

Received: Febr 18, 2003; *accepted:* March 22, 2003

Correspondence: Irene PECORELLA, MD, Dipartimento di Medicina Sperimentale e Patologia, Università degli Studi "La Sapienza", Viale Regina Elena, 324 – 00161 ROMA, Italy Tel. and fax ++39-0649970842, e-mail: irenepecorella@virgilio.it

Discussion

RICT is a common incidental and clinically silent finding in kidneys of patients older than age 50, accounting for 30% of all postmortems.² Its name was coined basing on the light and electron microscopic similarities of the cells to those normally located between Henle's loop and the vasa recta. Macroscopically, the lesion is round to oval, non-capsulated, up to 7 mm in diameter, pale gray to yellow, and located in the midportion of the medulla. Renal oxalate deposits are, on the other hand, a far less common postmortem findings, accounting for 6.4% of consecutive cases, but their occurrence is markedly increased (50% to 70%) in patients dying due to renal insufficiency,¹ or graft failure.³ We have already reported the presence of a mucopolysaccharidic matrix surrounding oxalate deposits in AIDS patients showing oxalosis of unusual sites (eyes).⁴ Interestingly, a prominent feature of RICT is the high acid mucopolysaccharide content.²

The combination of calcium oxalosis and RICT has not been reported before, and could be purely coincidental. Nevertheless, there were no further deposits in the remain-

ing kidney tissue of this patient. Upon revision of a further 25 postmortems performed in AIDS individuals, we observed the presence of calcium oxalates in 15 (60%) kidneys; in 6 of them, the deposits were rather abundant. There was, however, no clear correlation with clinical or histological signs of renal dysfunction. We believe that the occurrence of oxalates in the postmortem tissues of our AIDS population might possibly be due to systemic biochemical alterations of the glycosaminoglycans as a result of profound metabolic disturbances.

References

1. *Chaplin AJ*. Histopathological occurrence and characterisation of calcium oxalate: a review. *J Clin Pathol* 30: 800-811, 1977.
2. *Lerman RJ, Pitcock JA, Stephenson P, Muirhead EE*. Renomedullary interstitial cells tumor (formerly fibroma of renal medulla). *Hum Pathol* 3: 559-568, 1972.
3. *Memeo L, Pecorella I, Ciardi A, et al*: Calcium oxalate microdeposition in failing kidney grafts. *Transpl Proc* 33: 1262-1265, 2001.
4. *Pecorella I, McCartney ACE, Lucas S, et al*: Histological study of oxalosis in the eye and adnexa of AIDS patients. *Histopathology* 27: 431-438, 1995.