

CASE REPORT

Malignant Peripheral Nerve Sheath Tumors Associated With Neurofibromatosis Type 1

Report of 4 cases

Bilge BILGIC,¹ Lora Esberk ATES,¹ Misten DEMIRYONT,¹ Harzem OZGER,² Yavuz DIZDAR³

¹Department of Pathology, ²Department of Orthopaedic Surgery, ³Institute of Oncology, Department of Radiation Oncology, Istanbul University, Istanbul Medicine Faculty, Capa, Istanbul, Turkey

We report 4 cases of malignant peripheral nerve sheath tumors (MPNST) with neurofibromatosis type 1 (NF1). Mean age was 29.5. Two of them had a family history. Three of them were male. All of them had enlarging mass and pain in the background of neurofibromas. Locations were popliteal, thigh and forearm. The masses were greater than 5 cm in diameter in each case. In two cases the mass was showing continuity with a nerve. One patient had a nonossifying fibroma as well as a MPNST. Wide

Keywords: Neurofibromatosis, malignant peripheral nerve sheath tumours, sarcoma, nonossifying fibroma

excision and radiotherapy were applied to three of the patients. One of them did not take any therapy after surgical resection. Two of the patients died of lung metastases after a mean period of 12.5 months. In a majority of NF1 patients MPNST emerges from a preexisting neurofibroma. The patients with NF1 are at greatest risk for developing sarcomas, so they should be followed closely. (Pathology Oncology Research Vol 9, No 3, 201–205)

Introduction

NF1 is an autosomal dominant inherited genetic disorder¹⁵. It is associated with deletions, insertions or mutations in the NF1 gene. This gene is a tumor suppressor gene located in the pericentromeric region of chromosome 17.¹⁰ Neurofibromas are the hallmark of the disease and usually appear during childhood or adolescence after café au lait spots. Skeletal abnormalities such as scalloping of the vertebrae, congenital bowing of long bones with pseudoarthrosis, unilateral orbital malformations and cystic osteolytic lesions occur in almost 40 % of patients with this disease.¹⁵ The MPNST account for approximately 5-10% of all soft tissue sarcomas, about one-fourth to one-half occur with NF1. Patients with NF1 are at greatest risk for developing sarcomas 10-20 years after the neurofibromas occur.

MPNST is typically a disease of adult life. Most tumors occur in patients 20-50 years of age.^{4,8,15,16} MPNST arising in people with NF1 are usually diagnosed at an earlier age and have been reported to carry a worse prognosis than those arising in patients without NF1.^{2,4,7,14} The most common anatomic sites include the proximal portions of the upper and lower extremities⁸ and the trunk.^{4,15} In this report we present 4 cases of MPNST arising in patients with NF1 (*Table 1*).

Case Report

Case 1 is a 29 year old male with multiple neurofibromas and café au lait spots on his body. He had no family history. He first reported to the hospital in 1997 with an enlarging mass on his upper thigh. A wide excision was performed and radiotherapy was applied after the surgery. On the pathological examination there was a grey-white nodular shaped mass 8 x 7 x 5 cm in size. On microscopic examination the tumor was composed of spindle shaped cells arranged in interlacing bundles with coexisting neurofibromatous component which was less cellular and

Received: June 12, 2003; *accepted:* Sept 5, 2003

Correspondence: Lora Esberk ATES, Istanbul Universitesi Istanbul Tıp Fakültesi Temel Bilimler Binası Patoloji Anabilim Dalı, Capa, Istanbul, 34390, Türkiye; Tel: +90 212 6351171; fax: +90 212 6311367; e-mail: loraates@hotmail.com

Table 1. 4 cases of NF1 patients with MPNST

Case no	Age, sex	Family history	Location	Size (cm)	P53	Follow up
1	29, M	No	Thigh	8x7x5	- (<5%)	10 months later, an abdominal mass developed. Surgical operation performed. Surgical margins were (+). Patient died a year later.
2	38, M	Yes	Thigh-Opposite extremity	7x6x1.5 (MPNST) 3.2x2.5x1.6 (Neurofibroma)	-	13 months later, lung metastasis developed. Pneumonectomy performed. Patient died.
3*	25, M	Yes	Popliteal Thigh	10.5x7x6 (MPNST) 10x7x6 (Neurofibroma)	+(10%)	Patient is still alive without disease.
4	35, F	No	Forearm	Macroscopy made in another center	+ (30%)	12 months later, vertebrae and lung metastasis developed. Surgical operation performed. 26 months later patient died.

*This patient had also a nonossifying fibroma on his tibia.

myxoid. The diagnosis was MPNST developed on the background of a neurofibromatosis. Immunohistochemically S-100 protein was focally positive in the malignant areas and less than 5% of the tumoral cells were positive with p53 protein. On the follow up, 10 months later, the patient had an anterior abdominal mass. A surgical operation was performed. Histologically the tumor composed of spindle shaped, large atypical cells in an interlacing bundle pattern. The diagnosis was MPNST. The surgical margins were positive. The patient died a year later.

Case 2 is a 29 year old male with multiple neurofibromas and café au lait spots on his body. He had a family history. In 1997 he reported to the hospital with an enlarging mass and pain on his posterior thigh during a 6 months period. Firstly a thru-cut material was sent to our department. Histologically there was a sarcomatous malignant tumor composed of cells with indistinct cytoplasm and hyperchromatic fusiform nuclei with focally necrotic areas. A tumoral resection on his extremity and a neurofibroma excision were performed on the opposite extremity. The mass was 7 x 6 x 1.5 cm in size, grey-white, centrally necrotic, continuous with sciatic nerve (*Figure 1*). Microscopic examination revealed diffuse infiltration of spindle shaped cells with large, hyperchromatic wavy nuclei and focally necrotic areas (*Figure 2*). Immunohistochemically S-100 protein was focally strong positive, p53 protein was negative in the tumoral cells. On the histopathological examination of the nerve adjacent the mass, there was a myxoid degeneration and plexiform nodularity. The excised neurofibroma from the opposite extremity measured 3.2 x 2.5 x 1.6 cm and histologically spindle cells on

a myxoid stroma and wavy short collagen fibers were seen. Cellularity was low. Immunohistochemically p53 protein was negative.

Thirteen months later, lung metastases occurred; pneumonectomy and third and fourth costa resection were performed. On the cut surface of the lung there were multiple nodules. Microscopic examination of the lung and the costas revealed similar morphology with the first operation material. The diagnosis was metastases of MPNST. Surgical margins and pleural invasion were positive. The patient died soon after.

Case 3 is a 25 year old male with a family history and multiple neurofibromas, *café au lait* spots on his body. The patient had multiple masses on his body lasting for 7 years and enlarging masses both on popliteal area (*Figure 3*)

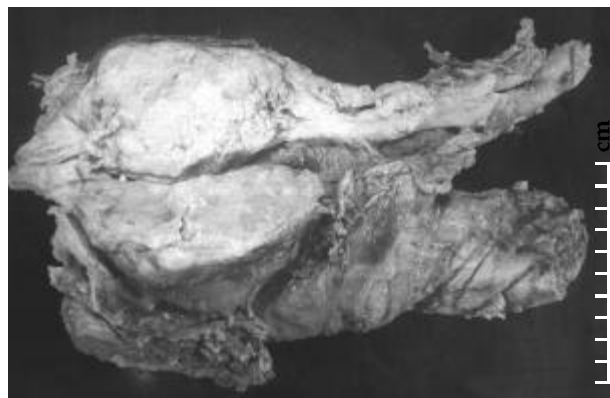


Figure 1. Macroscopic appearance of the tumor in case 2: mass adjacent the sciatic nerve.

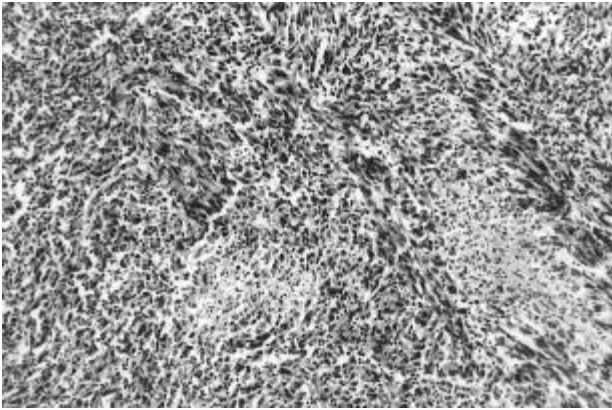


Figure 2. Foci of necrosis in MPNST, case 2 (H & E, x 125).

and thigh during a 5 year period. Surgical mass excision was performed. On macroscopic examination of the popliteal mass, a grey-yellow focally necrotic 10.5 x 7 x 6 cm mass was seen (*Figure 4*). Histopathologically there were spindle shaped cells arranged in an interlacing bundle pattern, necrosis and mitosis were seen. The diagnosis was MPNST developed on the background of a neurofibroma (*Figure 5*). Immunohistochemically S-100 protein

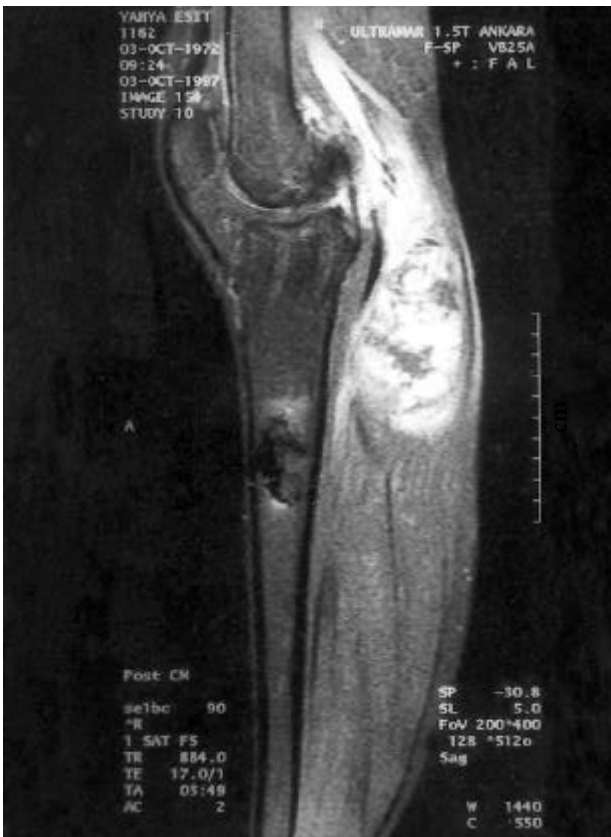


Figure 3. Radiography of soft tissue mass with a tibial osseous lesion.

was focally positive, p53 protein was positive in 10 % of the tumoral cells. The surgical margins were negative.

The mass which was excised from the thigh measured 10 x 7 x 6 cm. The cut surface was homogenous yellowish and focally gelatinous. Microscopically spindle shaped cells with eosinophilic cytoplasm settled in a loose myxoid stroma and there were sparse cells with large hyperchromatic nuclei in between the disorganized short collagen bundles. The diagnosis was a neurofibroma. Immunohistochemically S-100 protein was diffusely positive, p53 protein was negative. There was also a spongiotic bone material taken from tibia. This was diagnosed as a nonossifying fibroma composed of spindle shaped cells in a storiform pattern with giant cells and foamy histiocytes (*Figure 6*). Adjuvant radiotherapy was applied to the patient after the surgery. The patient is still alive without disease.

Case 4 is a 35 year old female with multiple neurofibromas and café au lait spots on her body. She had no family history. Twelve years ago a neurofibroma excision was made from her eyelid and in 1996 a mass excision was performed from her forearm in another hospital. The diagnosis was a MPNST. Adjuvant radiotherapy was applied after the surgery. A year later, in 1997, the patient had an enlarging mass and pain on her back. Radiologically there was a lytic lesion on eleventh thoracic vertebrae. MR images revealed a mass lesion destroying the vertebrae with soft tissue expansion into the spinal canal. Transthoracic corpectomy, reconstruction were performed. The pathological examination revealed a MPNST with necrosis, spindle and pleomorphic cells with indistinct cytoplasm. Immunohistochemically S-100 protein was negative, p53 protein was positive in 20% of the tumoral cells. Anthracyclin based adjuvant chemotherapy was designed. After 8 months, a lumbar paravertebral mass and lung metastases occurred. The patient died in a week.

Discussion

NF1 is an autosomal dominant inherited genetic disease and affects 1 in every 2500 to 3000 live births. Half of the patients with this disease have affected family members, the remaining patients represents new mutations.^{7,15} NF1 primarily affects the peripheral nervous system and is often characterized by large numbers of neurofibromas. Although these growths are benign, a minority of patients with NF1 show an increased incidence of malignancy such as MPNST, astrocytoma and childhood CML.^{1,10} NF1 gene is a tumor suppressor gene located in the proximal long arm of chromosome 17 and encodes neurofibromin. This protein demonstrates significant homology to proteins that activates the GTPase activity of RAS oncogene product.¹⁰ Loss of heterozygosity of chromosome 17 in NF1 locus is

identified in 13% of dermal neurofibromas, 40% of plexiform neurofibromas and 60% of MPNST.¹¹

NF1 is diagnosed in an individual with two or more of the following signs: café au lait macules, two or more neurofibromas of any type or one plexiform neurofibroma, freck-

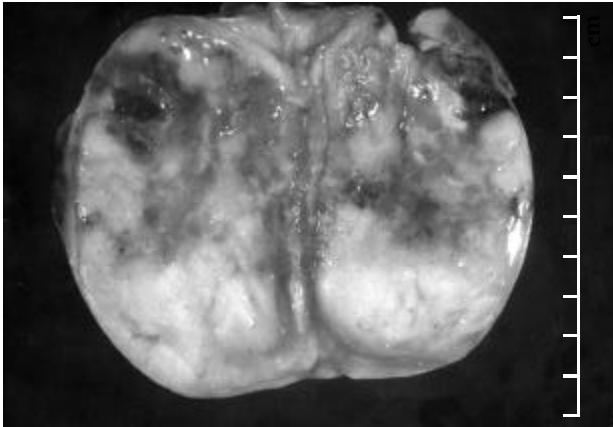


Figure 4. Macroscopic appearance of MPNST in case 3.




Figure 5. Transformation zone of neurofibromatous component to malignant form in case 3 (H & E, x 125).

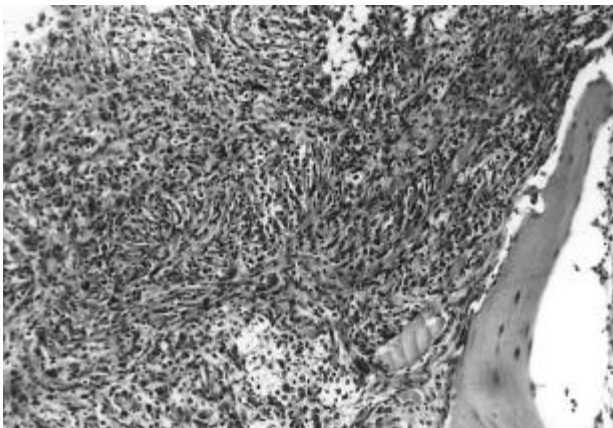


Figure 6. Nonossifying fibroma in case 3 (H & E, x 125).

ling in the axillary or inguinal region, optic glioma, two or more Lisch nodules, a distinctive osseous lesion, first degree relatives with NF1. Neurofibromas usually appear during childhood or adolescence after the café au lait spots.¹⁵

Skeletal abnormalities occur in almost 40 % of the patients with this disease. All of our patients had café au lait spots, multiple neurofibromas, two of them had family history of NF1. One patient had a nonossifying fibroma as well as MPNST.

The patients with neurofibromatosis are at greatest risk for developing sarcomas after 10 years or longer.¹⁵ The incidence of MPNST arising in neurofibromatosis is 4.6% and 0.001 % in general population⁴. Patients with NF1 are recommended to be followed closely for MPNST development.¹⁴ In a majority of NF1 patients, MPNST emerges from a preexisting neurofibroma.^{4,8,9,15,17,18} This neurofibroma is usually either a plexiform neurofibroma or a localized intraneural neurofibroma involving a medium sized nerve or nerve plexus.^{11,18} Plexiform neurofibroma is seen only in association with NF1.^{6,13,18} The nerve origin could be surgically identified in 45% to 56% of the NF1 patients. Microscopically a background of neurofibroma was observed in all of our patients; two of them were plexiform neurofibroma.

Histologically MPNST is characterized by mild to significant hypercellularity, nuclear atypia, increased mitotic index.⁴ The nuclei are wavy, buckled or comma shaped. The cytoplasm is lightly stained, usually indistinct and spindle shaped. The cells are arranged in sweeping fascicles. Densely cellular fascicles alternate with hypercellular, myxoid zones.¹⁵ Heterotopic elements and divergent differentiation to rhabdomyosarcoma, osteosarcoma, chondrosarcoma, angiosarcoma can be identified.^{3,8} Most of these lesions were associated with NF1.³ In our cases none of these differentiation was seen.

There is a study which reveals the genetic imbalances in sporadic and hereditary MPNST. In 20 sporadic MPNST, the most frequent gains were 8q, 5p, 6p and 20q. In nine MPNST from patients with Recklinghausen's disease, the most frequent gains were in 7q, 8q, 15q and 17q.¹²

Patients with NF1 develop MPNST in their adult life.^{2,4,9,14} Men predominate in some studies^{2,4} and in other studies women seem to be equal to men.⁹ Our patients were at the ages between 24 and 36, and three were men while one was woman. The initial complaint of the NF1 patients with MPNST is an enlarging mass and pain.^{2,4,8,9} The most common anatomic sites include the proximal portions of the upper and lower extremities⁸ and the trunk.^{4,15} Immunohistochemically S-100 protein, the most widely used antigen for neural differentiation, can be identified in 50-90% of MPNST. The staining is focal and limited to a small number of cells.^{8,15} In a study S-100 protein, myelin basic protein and Leu-7 were demonstrated with frequencies of 58%, 47% and 52% of MPNST.¹⁶

Most MPNST are high grade sarcomas with a likelihood of producing local recurrence and distant metastases. The local recurrence rate varies from 40% to 65% and the metastatic rate varies from 40% to 68%.¹⁵ One of our patients developed abdominal metastases after 10 months. Two of the patients developed lung metastases; one of them had vertebrae metastases, also. Twelve - 13 months after the first operation two of them died. The most common metastatic site for MPNST is the lung followed by bone.^{8,15} Grossly the tumors of patients with von Recklinghausen's disease frequently measure more than 5 cm.^{4,8} Three of our patients had tumor sizes between 7 and 11 cm. Patients with NF1 and large tumors had a 5 year survival of 9%.⁴

Although patients with tumors in the extremities had a better prognosis than head and neck lesions, location did not appear to be a major prognostic factor.^{2,4} But some studies reveal that patients with limb lesions had longer survival than patients with nonlimb lesions.⁹ Some reports demonstrate that patients who develop MPNST with NF1 have reduced survival rates,⁴ but others find no difference.¹⁴ NF1 patients with a family history experienced longer periods of disease-free survival than those without a family history. Aggressive surgery significantly improved disease-free survival times. Patients who had local excisions, wide local excisions or amputations had longer disease-free survival times than those who had subtotal resections.^{4,14} The usefulness of adjuvant radiation therapy in MPNST is not determined, but all tumors should receive adjuvant radiation therapy. The role of chemotherapy is unclear.¹⁴

The detection of malignant change in plexiform neurofibromas using clinical characteristics, MRI and even biopsy may be difficult.¹⁸ Fluorodeoxyglucose positron emission tomography (¹⁸FDGPET) has been determined as a useful noninvasive method of identifying malignant change in plexiform neurofibromas in patients with NF1.⁵ The biology of malignant transformation in patients with NF1 is still unknown. But there is some evidence to support the role for loss of p53 gene function in molecular pathogenesis of MPNST, as immunohistochemically p53 reactivity is obtained in more than half of MPNST but not in neurofibromas.^{15,18} We applied immunohistochemical method to detect p53 mutation (DO7 clone) in our cases. The neurofibromas were absolutely negative. When we applied p53 protein to our MPNST patients half of the cases were positive and half of them were negative. Less than 3% of the tumoral cells were positive in case 1, we evaluated as negative. In case 2, none of the tumoral cells were positive. 10% of the tumoral cells in case 3 and 30% of the tumoral cells in case 4 were positive.

In conclusion MPNST associated with NF1 are high grade sarcomas with short survival. The patients with NF1 should be closely followed to detect the malignant transformation at an early stage.

References

1. *Blatt J, Jaffe R, Deutsch M, et al:* Neurofibromatosis and childhood tumors. *Cancer* 57: 1225-1229, 1986
2. *D'Agostina AN, Soule EH, Miller RH:* Sarcomas of the peripheral nerves and soft tissues associated with multiple neurofibromatosis (Von Recklinghausen's Disease). *Cancer* 16: 1015-1027, 1963
3. *Ducatman BS, Scheithauer BW:* Malignant peripheral nerve sheath tumors with divergent differentiation. *Cancer* 54: 1049-1057, 1984
4. *Ducatman BS, Scheithauer BW, Piepgras DG, et al:* Malignant peripheral nerve sheath tumors a clinicopathologic study of 120 cases. *Cancer* 57: 2006-2011, 1986
5. *Ferner RE, Lucas JD, O'Doherty MJ, et al:* Evaluation of 18 Fluorodeoxyglucose positron emission tomography (18 FDG PET) in the detection of malignant peripheral nerve sheath tumors arising from within plexiform neurofibromas in neurofibromatosis 1. *J Neurol Neurosurg Psychiatry* 68: 353-357, 2000
6. *Halliday AL, Sobel RA, Martuza RL:* Benign spinal nerve sheath tumors: their occurrence sporadically and in neurofibromatosis types 1 and 2. *J Neurosurg* 74: 248-253, 1991
7. *Hajdu SI:* Peripheral nerve sheath tumors, histogenesis, classification and prognosis. *Cancer* 72: 3549-3552, 1993
8. *Hruban RH, Shiu MH, Senie RT et al:* Malignant peripheral nerve sheath tumors of the buttock and lower extremity. A study of 43 Cases. *Cancer* 66: 1253-1265, 1990
9. *King AA, DeBaun MR, Riccardi VM, et al:* Malignant peripheral nerve sheath tumors in neurofibromatosis 1. *Am J Med Genet* 93: 388-392, 2000
10. *Nussbaum RL, McInnes RR, Willard HF:* Genetics In Medicine. Genetics and Cancer, W. B. Saunders Company: Philadelphia, 2001.
11. *Rasmussen SA, Overman J, Thomson SAM, et al:* Chromosome 17 loss-of-heterozygosity studies in benign and malignant tumors in neurofibromatosis type 1. *Genes, Chromosomes, Cancer* 28: 425-431, 2000
12. *Schmidt H, Würl P, Taubert H, et al:* Genomic imbalances of 7p and 17q in malignant peripheral nerve sheath tumors are clinically relevant. *Genes, Chromosomes, Cancer* 25: 205-211, 1999
13. *Topsakal CD, Akdemir I, Tiftikci M, et al:* Malignant schwannoma of the sciatic nerve originating in a spinal plexiform neurofibroma associated with neurofibromatosis type 1. *Neurol Med Chir (Tokyo)* 41: 551-555, 2001
14. *Wanebo JE, Malik JM, Vandenberg SR, et al:* Malignant peripheral nerve sheath tumors. A clinicopathologic study of 28 cases. *Cancer* 71: 1247-1253, 1993
15. *Weiss SW, Goldblum JR:* Benign tumors of the peripheral nerves. Malignant tumors of the peripheral nerves. *Enzinger and Weiss's Soft Tissue Tumors*. Mosby, St Louis, 2001.
16. *Wick MR, Swanson PE, Scheithauer BW et al:* Malignant peripheral nerve sheath tumor. An immunohistochemical study of 62 cases. *Am J Clin Pathol* 87: 425-433, 1987
17. *Woodruff JM, Christensen WN:* Glandular peripheral nerve sheath tumors. *Cancer* 72: 3618-3628, 1993
18. *Woodruff JM:* Pathology of tumors of the peripheral nerve sheath in type 1 neurofibromatosis. *Am J Med Genet (Semin Med Genet)* 89: 23-30, 1999