

CASE REPORT

Malignant Melanoma with Gall Bladder Metastasis as a Second Neoplasm in the Course of Prostate Cancer

Grzegorz ŚWIĄTONIOWSKI,¹ Grzegorz MAZUR,² Agnieszka HAŁOŃ,³ Grzegorz ROZUMEK,¹
Maria DĄBROWSKA,¹ Radosław ZAWISZA,⁴ Edmun PRUDLAK¹

¹Department of Internal Medicine, ⁴th Academic Military Hospital, ²Department of Haematology, Blood Neoplasms and Bone Marrow Transplantation, Wrocław Medical University, ³Department of Pathological Anatomy, Wrocław Medical University, ⁴Department of Surgery, ⁴th Academic Military Hospital, Wrocław, Poland

Malignant melanoma is a neoplasm with an often unpredictable course and metastases potentially affecting all organs of the human body. Metastases into the gall bladder are rare. The role of hormonal background in the development and progression of malignant melanoma has not been established. The

authors present a case of a 63-year-old man who had initially undergone long-term hormone therapy for the treatment of prostate cancer, and later presented with melanoma metastatic to the gall bladder. (Pathology Oncology Research Vol 10, No 4, 243–245)

Keywords: prostate cancer, malignant melanoma, hormone therapy, second neoplasm

Introduction

Malignant melanoma is neoplasm metastasizing to all organs of the human body. The occurrence of metastases in the gall bladder is rare and has only been reported in the literature exceptionally.^{4,5,8,10,12,15}

The role of hormonal conditioning in the development and progression of malignant melanoma, and the possibility for hormonal treatment of the aforementioned neoplasm has been studied for many years.^{1,2,11,13} In our report we present a case of a patient with prostate cancer treated with hormone therapy, who later developed malignant cutaneous melanoma metastasizing to the gall bladder. Due to the extended survival in oncologically treated patients, and to the late complications of treatment, the occurrence of second neoplasms is a crucial issue of contemporary oncology.

Case report

In 1993, a 63-year-old man was diagnosed with prostate cancer, based on fine needle biopsy (No. 3397/93). Disease stage was determined as T₃N_xM₀. Surgical castration was performed, and in consideration of the lack of patient consent for radical treatment, flutamide was administered. The drug was used until 2000 with no evidence of dissemination by radiological examinations, but then a tendency of increase in prostate-specific antigen (PSA) level was observed. The second course of hormone therapy (cyproterone) was administered, and after patient consent was obtained, radical radiotherapy was applied. From October to December 2000 the patient was exposed to 64 Gy radiation to the pelvis minor. After radiotherapy, estramustine was included in the treatment because of a permanent increase in PSA level.

In June 2001 the patient presented dissemination of the disease to retroperitoneal and left supraclavicular lymph nodes. At that time an attempt at palliative chemotherapy with mitoxantrone and prednisone was made. The patient was given eight courses of chemotherapy, and partial regression was obtained, involving both a reduction of the diameter of lymph nodes and a decrease in PSA level. Subsidence of algescic complaints and improvement in quality of life were observed.

Received: Oct 13, 2004; *accepted:* Nov 17, 2004

Correspondence: Grzegorz MAZUR, MD, PhD, Department of Haematology, Blood Neoplasm and Bone Marrow Transplantation, Wrocław Medical University, Pasteura 4, 50-367 Wrocław, Poland. Tel: +48 71 7842576, fax: +48 71 7840112, e-mail: grzegmaz@hemat.am.wroc.pl

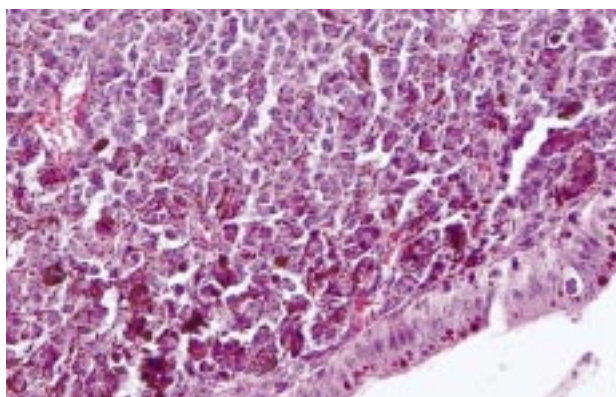


Figure 1. Gall bladder metastasis of malignant melanoma

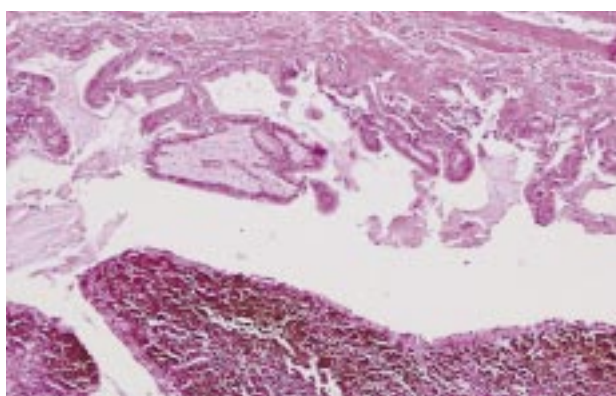


Figure 2. Microscopic feature of gall bladder metastasis of malignant melanoma (x40)

During consecutive routine examinations, a tumor-like lesion within the wall of the gall bladder was detected by sonography. Owing to the occurrence of pain in the right epigastric region and risks of complications involving the gall bladder, in February 2002 the patient underwent cholecystectomy to clarify its pathological relevance. Histologically (examination No. 1983/02), the tumor was a metastasis of malignant melanoma. Scrupulous skin inspection revealed a blackish focus of 3 mm in diameter in the submental region, which had been noticed by the patient one month earlier. Figure 1 and 2 present microscopic features of gall bladder metastasis of malignant melanoma.

After surgery, tamoxifen (80 mg daily dose) was administered, but only short-time stabilization of the disease was achieved. The patient died of metastatic spreading of the disease to the central nervous system in May 2002.

Discussion

In our discussion and commentary we would like to point out the unpredictable course and metastasis formation of malignant melanoma, as well as the probability of its hormonal background.

Metastases of a malignant melanoma in the gall bladder

Metastasizing malignant melanomas can affect all organs in the human body. However, isolated metastatic spreading into the gall bladder is rare. Individual asymptomatic cases,^{8,15} as well as ones producing symptoms mimicking cholecystitis, even leading to perforation of the gall bladder,^{10,12} have been reported. A procedure serving both diagnostic and therapeutic purposes is cholecystectomy. The first laparoscopic cholecystectomy for a metastasis of malignant melanoma in the gall bladder was described in 1997.¹⁵

According to the literature, primary malignant melanoma in the gall bladder is a controversial issue, and it is still far from clear whether primary melanoma of this organ is a definite entity in itself. To help in the differentiation between primary and secondary malignant melanoma, certain pathological and clinical criteria should be fulfilled in the diagnosis of primary melanoma:

- (1) the tumor must be solitary, and arise from the mucosal surface of the gall bladder;
- (2) it must either be papillary or polypoid;
- (3) it should display junctional activity, or any other obvious primary sites should be excluded by anamnesis and examination.^{4,5}

Steroid hormones and malignant melanoma

The relationship between sex hormones and the occurrence and progression of malignant melanomas is a matter of dispute and controversy. Since 1951, a number of case reports have suggested a connection between pregnancy and malignant melanoma. They have suggested that pregnancy may induce or exacerbate melanoma. Likewise, there has been concern over the effect of exposure to oral contraceptives (OCs) or hormone replacement therapy (HRT). Grin et al have critically reviewed controlled clinical trials to assess the effect of pregnancy on the prognosis of melanoma, and epidemiological data to evaluate melanoma risk after exposure to OCs and HRT. The authors concluded that pregnancy before, during or after the diagnosis of melanoma does not appear to influence the 5-year survival rate, and exposure to OCs or HRT does not increase the risk of melanoma.² Feskanich et al. presented different data. They examined prospectively the association between the use of OCs and diagnosis among 183,693 premenopausal women. A significant, twofold increase in melanoma risk was observed among current OC users, especially with 10 or more years of use, compared to never users. The risk did not appear elevated among past OC users, even with long duration of use.¹

Epidemiological data clearly show a survival benefit for female patients with metastatic melanoma, but the mechanism of this relationship is unresolved. Miller et al. did not

reveal any evidence of the presence of estrogen receptors (ER) in melanoma cells. Immunocytochemical assay identified only two ER-positive lesions out of 69 cases investigated. There were no significant changes in estrone or androstenedione levels for male or female patients with disease progression.¹¹ Similar results were reported by Richardson and colleagues. They did not reveal a relationship between circulating sex steroids and disease progression in females, but reported a significant reduction in circulating estrone level with disease progression in male patients.¹³

Tamoxifen in the treatment of metastatic melanoma

Tamoxifen (TAM), an estrogen antagonist routinely used in the treatment of breast cancer, has been used in clinical trials for patients with melanoma since the 1970s. The effectiveness of therapy with tamoxifen, both as a single agent and in combination, is still a matter of controversy. Toma et al. in a review summarizing the available preclinical and clinical evidence in this field showed that tamoxifen has no useful activity as monotherapy (most published response rates reaching less than 10%).¹⁶ Similarly, tamoxifen combined with different cytotoxic agents did not improve response rate or survival. Only one controlled trial showed significant improvement in both response rate and survival (dacarbazine plus TAM).^{14,16} Nevertheless, it has been demonstrated that cisplatin (DDP) and tamoxifen (TAM) act synergistically in killing human melanoma T-289 cells.⁶ Furthermore, TAM at adequate doses inhibited *in vitro* growth of human melanoma cell line SK-Mel-28.⁹ Since according to the majority of reports melanoma cells do not express classical estrogen receptors, and no melanoma tumors showed immunohistochemical evidence of ERs,^{3,9} it is suggested that the cytotoxic effect of TAM on melanoma cells could depend on interference with the function of insulin-like growth factor-1 receptor (IGF-1R),⁷ or the intracellular antiestrogen-binding sites.⁶ It is suggested that the induction of apoptosis, probably through the inhibition of protein kinase C, as well angiogenesis inhibition partly mediated by transforming factor growth beta (TGF-beta) stimulation, are alternative ways through which TAM suppresses melanoma cell growth, independently of the expression of estrogen receptors.¹⁶

Conclusions

In spite of the potential possibilities of systemic treatment in malignant melanoma (chemo-, immuno-, and hormone therapy), the prognosis of this malignancy is poor,

especially in advanced, disseminated stages of disease. As we have shown, malignant melanoma may appear as a second neoplasm in the course of primary disease with relatively good response for systemic treatment. In such a situation, disseminated malignant melanoma limits the patient's survival.

References

1. Feskanich D, Hunter DJ, Willett WC, et al: Oral contraceptive use and risk of melanoma in premenopausal women. *Br J Cancer* 81: 918-923, 1999
2. Grin CM, Driscoll MS, Grant-Kels JM: The relationship of pregnancy, hormones, and melanoma. *Semin Cutan Med Surg* 17: 167-171, 1998
3. Grostern RJ, Slusker-Shternfeld I, Bacus SS, et al: Absence of type I estrogen receptors in choroidal melanoma: analysis of Collaborative Ocular Melanoma Study (COMS) eyes. *Am J Ophthalmol* 131: 788-791, 2001
4. Heath DI, Womack C: Primary malignant melanoma of the gall bladder. *J Clin Pathol* 41: 1073-1077, 1988
5. Higgins CM, Strutton GM: Malignant melanoma of the gall bladder – does primary melanoma exist? *Pathology* 27: 312-314, 1995
6. Jones JA, Albright KD, Christen RD, et al: Synergy between tamoxifen and cisplatin in human melanoma cells is dependent on the presence of antiestrogen-binding sites. *Cancer Res* 57: 2657-2660, 1997
7. Kanter-Lewensohn L, Girnita L, Girnita A, et al: Tamoxifen-induced cell death in malignant melanoma Wells: possible involvement of the insulin-like growth factor 1 (IGF-1) pathway. *Mol Cell Endocrinol* 165: 131-137, 2000
8. Kohler U, Jacobi T, Sebastian G, Nagel M: Laparoscopic cholecystectomy in isolated gallbladder metastasis of malignant melanoma. *Chirurg* 71: 1517-1520, 2000
9. Lama G, Angelucci C, Bruzzese N, et al: Sensitivity of human melanoma cells to oestrogens, tamoxifen and quercetin: is there any relationship with type I and II estrogen binding site expression? *Melanoma Res* 8: 313-322, 1999
10. Langley RG, Bailey EM, Sober AJ: Acute cholecystitis from metastatic melanoma to the gall-bladder in a patient with a low-risk melanoma. *Br J Dermatol* 136: 279-282, 1997
11. Miller JG, Gee J, Price A, et al: Investigation of estrogen receptors, sex steroids and soluble adhesion molecules in the progression of malignant melanoma. *Melanoma Res* 7: 197-208, 1997
12. Ostick DG, Haqqani MT: Obstructive cholecystitis due to metastatic melanoma. *Postgrad Med J* 52: 710-712, 1976
13. Richardson B, Price A, Wagner M, et al: Investigation of female survival benefit in metastatic melanoma. *Br J Cancer* 80: 2025-2033, 1999
14. Rusthoven JJ: The evidence for tamoxifen and chemotherapy as treatment for metastatic melanoma. *Eur J Cancer* 34 (Suppl 3): S31-S36, 1998
15. Seelig MH, Schonleben K: Laparoscopic cholecystectomy for a metastasis of a malignant melanoma in the gallbladder. *Z Gastroenterol* 35: 673-675, 1997
16. Toma S, Ugolini D, Palumbo R: Tamoxifen in the treatment of metastatic malignant melanoma: still a controversy? *Int J Oncol* 15: 321-337, 1999