

## ARTICLE

## Immunohistochemical Expression of EGFR and p-EGFR in Oral Squamous Cell Carcinomas

Yukihiro HIRAISHI, Takeshi WADA, Ken NAKATANI, Kenji NEGORO, Shigeyuki FUJITA

Department of Oral and Maxillofacial Surgery, Wakayama Medical University, Wakayama, Japan

Epidermal growth factor receptor (EGFR) is a tyrosine kinase receptor of the ErbB family, which is expressed or highly expressed in a variety of solid tumors, including oral cancers. High EGFR expression has been correlated with tumor size, metastasis and survival. In recent years, EGFR has been considered a promising target for monoclonal antibody therapy. A total of 52 patients with oral squamous cell carcinoma (OSCC) were selected for EGFR and phosphorylated EGFR (p-EGFR) detection. Immunohistochemical staining was performed to evaluate EGFR and p-EGFR expression. Positive EGFR and p-EGFR staining was present in 92.3% (48/52) and

98.0% (51/52) of all cases, respectively. High EGFR and p-EGFR expression was present in 63.4% (33/52) and 69.2% (36/52) of all cases, respectively. EGFR and p-EGFR expression did not correlate with the clinical factors tumor stage, regional lymph node metastasis, or distant metastasis. However, a statistically significant correlation was identified between high EGFR expression and the pathologic factor tumor invasion. As a conclusion, the majority of OSCCs highly express EGFR and p-EGFR, indicating the importance of studying the efficacy of anticancer therapy targeting these signal factors. (Pathology Oncology Research Vol 12, No 2, 87–91)

*Key words:* EGFR, p-EGFR, oral squamous cell carcinomas

### Introduction

Proliferation and differentiation of cancers are controlled by growth factors and their receptors on cancer cell surfaces. Epidermal growth factor receptor (EGFR) is a tyrosine kinase receptor of the ErbB family, which is expressed or highly expressed in a variety of solid tumors, including oral cancer.<sup>1</sup> EGFR activation induces activation of several downstream intracellular substrates, leading to mitogenic signaling and other tumor-promoting cellular activities.<sup>2</sup> In human tumors, high expression of EGFR correlates with a more aggressive clinical course,<sup>1</sup> and has been reported to be a useful diagnostic and prognostic marker.<sup>3</sup> In recent years, EGFR has been considered a promising target for monoclonal antibody therapy. Since most oral cancers are epithelial in origin, they should have a high probability of expressing both EGFR and phosphorylated EGFR (p-EGFR). The aim of the present study

was to examine immunohistochemically the expression of EGFR and p-EGFR in oral squamous cell carcinomas (OSCCs) and its correlation to clinicopathological data.

### Materials and methods

#### *Patients and specimens*

The study comprised a total of 52 randomly selected patients (33 males and 19 females) with oral and maxillofacial squamous cell carcinomas, treated at the Department of Oral and Maxillofacial Surgery, Wakayama Medical University Hospital between 1990 and 2002. The patients ranged in age from 49 to 91 years, with a mean age of 67.5 years. The primary malignant tumors were located on the lower gingiva in 18 cases, the tongue in 11 cases, the upper gingiva in 8 cases, the oral floor in 8 cases, the maxillary sinus in 3 cases, the hard palate in 2 cases, and the oropharynx in 2 cases. Tumor staging was performed according to the specifications of the TNM classification of malignant tumors (UICC 1997). The mode of tumor invasion was assessed according to the classification by Yamamoto et al<sup>4</sup> (Table 1). Using our grading system<sup>5</sup> (Table 1), the degree of lymphoid cell infiltration into surrounding proliferating tumor nests

*Received:* Febr 17, 2006; *accepted:* May 10, 2006

*Correspondence:* Yukihiro HIRAISHI, Department of Oral and Maxillofacial Surgery, Wakayama Medical University, 811-1 kimiidera, Wakayama 641-8509, Japan, Tel: + 81-73-441-0643, Fax: + 81-73-441-0643, E-mail: [hiraishi@wakayama-med.ac.jp](mailto:hiraishi@wakayama-med.ac.jp)

**Table 1. Histological grading of mode of invasion and S-LI grade**

<i>Mode of invasion</i>	
Grade 1	Well-defined borderline
Grade 2	Cords, less marked borderline
Grade 3	Groups of cells, no distinct borderline
Grade 4C	Diffuse invasion, cord-like type invasion
Grade 4D	Diffuse invasion, diffuse type invasion (Yamamoto et al <sup>4</sup> )
<i>S-LI grade (Degree of lymphoid cell infiltration in the surroundings of the proliferating tumor nests)</i>	
Grade 1	A few scattered lymphoid cells are seen
Grade 2	A definitive scattering of lymphoid cells is present
Grade 3	The lymphoid cell infiltration is dense and imparts an over-all lymphoid appearance (Wada et al <sup>5</sup> )

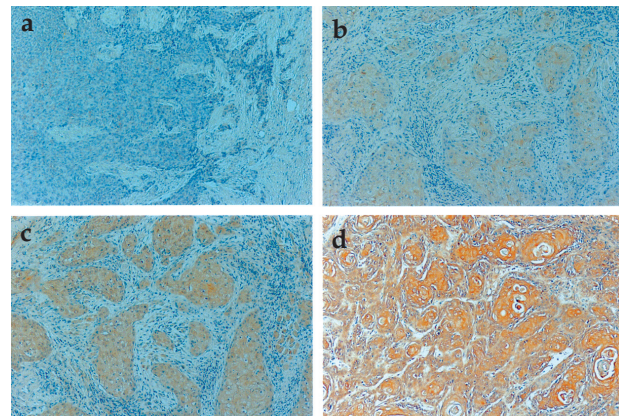
(S-LI grade) was categorized as Grade 1, Grade 2, or Grade 3. Archived formalin (10%)-fixed and paraffin-embedded biopsy specimens from the patients were examined after receiving informed consent by the patients or their families.

#### *Immunohistochemical staining*

Four- $\mu$ m-thick sections of paraffin-embedded tissues were mounted on precoated slides, air-dried overnight at 58°C, and deparaffinized in xylene and alcohol. After treatment with 5% skim milk containing 0.05% polyoxyethylene sorbitan monolaurate for 10 min at room temperature, sections were treated with 5% normal bovine serum albumin (BSA) for 5 min at 4°C to block non-specific binding. Endogenous peroxidase activity was blocked by incubation with 0.5% hydrogen peroxidase in methanol for 30 min. The sections were then incubated at 4°C overnight with a 1:200 dilution of rabbit polyclonal anti-EGFR antibody (Santa Cruz Biotechnology, CA, USA) as the primary antibody. To detect tyrosine phosphorylation of EGFR, a 1:200 dilution of goat polyclonal anti-p-EGFR (Tyr 1173) antibody (Santa Cruz Biotechnology) was used as the primary antibody. Immunohistochemical staining was performed with the LSAB system (DAKO, Kyoto, Japan) in accordance with the manufacturer's instructions. Specimens were counterstained with hematoxylin. EGFR or p-EGFR protein expression was evaluated using a light microscope.

#### *Evaluation of staining results*

Evaluation of staining results was performed in accordance with Putti's method<sup>6</sup> partly modified by us. The extent of staining was graded and scored as '0 points' for negative staining, '1 point' for <10%, '2 points' for 10%-



**Figure 1.** (a) Negative staining of EGFR is observed in upper gingiva. (b) Weak staining of p-EGFR is observed in tongue. (c) Moderate staining of EGFR observed in tongue. (d) Strong staining of EGFR observed in upper gingiva (original magnification  $\times 200$ )

50%, and '3 points' for >50% positive cells. Based on the intensity of positive reaction to EGFR or p-EGFR in the majority of tumor cells, the intensity of staining was graded and scored as '1 point' for weak staining (+) '2 points' for moderate staining (++) and '3 points' for strong staining (+++), compared with normal epithelium (Figure 1).

To determine an overall evaluation of positive staining for EGFR or p-EGFR, the overall score for each test spec-

**Table 2. Characteristics of immunoreactivity of staining extent and intensity of EGFR and p-EGFR**

<i>Staining</i>	<i>Cases (%)</i>	<i>Extent</i>		<i>Intensity</i>		
		<i>Score</i>	<i>Cases (%)</i>	<i>Score</i>	<i>Cases (%)</i>	
EGFR -	4 (7.7%)	-	-	-	-	
P-EGFR -	1 (2.0%)	-	-	-	-	
EGFR +	48 (92.3%)	1+	7 (14.6%)	1+	7 (100%)	
					2+	0 (0%)
					3+	0 (0%)
		2+	10 (20.8%)	1+	8 (80.0%)	
					2+	2 (20.0%)
					3+	0 (0%)
		3+	31 (64.5%)	1+	23 (74.2%)	
					2+	8 (25.6%)
					3+	0 (0%)
P-EGFR +51 (98.0%)		1+	3 (58.8%)	1+	3 (100%)	
					2+	0 (0%)
					3+	0 (0%)
		2+	18 (35.3%)	1+	12 (66.7%)	
					2+	6 (33.3%)
					3+	0 (0%)
		3+	30 (58.8%)	1+	25 (83.3%)	
					2+	5 (16.7%)
					3+	0 (0%)

imen was obtained by adding the extent of immunoreactivity score to the intensity score. In this study, an overall score  $\geq 1$  was defined as expression (positive staining), and  $\geq 4$  as high expression. The statistical significance of differences was analyzed by applying Fisher's exact test. The level of significance was set at  $P < 0.05$ .

### Results

#### EGFR and p-EGFR staining

Positive EGFR and p-EGFR staining was present in 92.3% (48/52) and 98.0% (51/52) of all cases, respectively. High EGFR and p-EGFR expression was present in 63.4% (33/52) and 69.2% (36/52) of all cases, respectively. The extent and

intensity of EGFR and p-EGFR immunoreactivity obtained from the oral squamous cell carcinoma specimens is given in Table 2. No correlation was found between extent score and intensity score. However, the mean overall score for p-EGFR was 3.67, a score slightly higher than the mean overall score of 3.42 for EGFR.

#### Clinical and pathologic characteristics of positive EGFR staining and high expression of EGFR

Table 3 shows the clinical and pathologic characteristics associated with EGFR expression. With respect to tumor invasion, a statistically significant correlation between high EGFR expression and advanced invasion

**Table 3. Characteristics of EGFR expression in patients with oral squamous cell carcinoma**

		EGFR-negative cases		EGFR-positive cases		P-value (a)	P-value (b)
		cases	staining (%)	expression (%)	high expression (%)		
Sex	Male	33	4 (12.1%)	12 (36.4%)	17 (51.5%)	0.11	0.06
	Female	19	0 (0%)	3 (15.8%)	16 (84.2%)		
Age	<65years	27	2 (7.4%)	8 (29.6%)	17 (63.0%)	1	1
	$\geq 65$ years	25	2 (8.0%)	7 (28.0%)	16 (64.0%)		
T stage	T1-T3	35	4 (11.4%)	11 (31.4%)	20 (57.1%)	0.498	0.421
	T4	13	0 (0%)	3 (23.0%)	10 (77.0%)		
	Unknown	4	0 (0%)	1 (25.0%)	3 (75.0%)		
N stage	N0-N1	43	3 (7.0%)	12 (27.9%)	28 (65.1%)	1	0.556
	N2-N3	5	1 (20.0%)	2 (40.0%)	2 (40.0%)		
	Unknown	4	0 (0%)	1 (25.0%)	3 (75.0%)		
M stage	M0	48	4 (8.3%)	14 (29.2%)	30 (62.5%)	1	1
	M1	0	0 (0%)	0 (0%)	0 (0%)		
	Unknown	4	0 (0%)	1 (25.0%)	3 (75.0%)		
TNM stage	I-III	32	3 (9.4%)	10 (31.3%)	19 (59.3%)	0.738	0.893
	IV	16	1 (6.3%)	4 (25.0%)	11 (73.3%)		
	Unknown	4	0 (0%)	1 (25.0%)	3 (75.0%)		
Differentiation	Well	36	2 (5.6%)	10 (27.8%)	24 (66.7%)	0.87	0.619
	Moderate	12	1 (8.3%)	4 (33.3%)	7 (58.3%)		
	Poor	4	1 (25.0%)	1 (25.0%)	2 (50.0%)		
Mode of invasion	Grade 1	2	1 (50.0%)	0 (0%)	1 (50.0%)	0.047	0.013
	Grade 2	9	2 (22.2%)	5 (55.6%)	2 (22.2%)		
	Grade 3	21	0 (0%)	6 (28.6%)	15 (71.4%)		
	Grade 4C	16	1 (6.3%)	2 (12.5%)	13 (81.3%)		
	Grade 4D	4	0 (0%)	2 (50.0%)	2 (50.0%)		
S-LI grade	Grade 1	16	1 (6.3%)	2 (12.5%)	13 (81.2%)	0.435	0.624
	Grade 2	27	3 (11.1%)	10 (37.0%)	14 (51.9%)		
	Grade 3	9	0 (0%)	3 (33.3%)	6 (66.7%)		

P-value (a): for comparison between expression and high expression; P-value(b): for comparison between negative, expression, and high expression

Unknown cases (Tx, Nx, Mx, TNM) were excluded from statistical analysis

( $P=0.047$ ) was observed. No other significant correlation between positive EGFR staining or high EGFR expression and clinical or pathologic characteristics was identified (Table 3).

*Clinical and pathologic characteristics of positive p-EGFR staining and high expression of p-EGFR*

Table 4 shows the clinical and pathologic characteristics associated with p-EGFR expression. No significant correlation between positive p-EGFR staining or high p-EGFR expression and clinical or pathologic characteristics was identified (Table 4).

**Discussion**

High EGFR expression is frequently observed in squamous cell carcinomas both in cell cultures and in human tumor specimens. Differences in immunohistochemical methodologies lead to different positive EGFR staining rates. Published reports of positive EGFR staining rates in head and neck squamous cell carcinomas have fallen in a range from 55% to 100%.<sup>7-11</sup> Our study of oral squamous cell carcinoma cases from the Department of Oral and Maxillofacial Surgery, Wakayama Medical University Hospital yielded a high positive EGFR staining rate (92.3%), with 63.4% of all cases exhibiting high EGFR

**Table 4. Characteristics of p-EGFR expression in patients with oral squamous cell carcinoma**

		EGFR-negative cases		EGFR-positive cases		P-value (a)	P-value (b)
		cases	staining (%)	expression (%)	high expression (%)		
Sex	Male	33	1 (3.0%)	11 (33.3%)	21 (63.7%)	0.359	0.593
	Female	19	0 (0%)	4 (21.1%)	15 (78.9%)		
Age	<65years	27	1 (3.7%)	6 (22.2%)	20 (74.1%)	0.367	0.362
	≥65years	25	0 (0%)	9 (36.0%)	16 (64.0%)		
T stage	T1-T3	35	1 (2.9%)	9 (25.7%)	25 (71.4%)	1	1
	T4	13	0 (0%)	4 (30.8%)	9 (69.2%)		
	Unknown	4	0 (0%)	2 (50.0%)	2 (50.0%)		
N stage	N0-N1	43	1 (2.3%)	11 (25.6%)	31 (72.1%)	0.606	0.647
	N2-N3	5	0 (0%)	2 (40.0%)	3 (60.0%)		
	Unknown	4	0 (0%)	2 (50.0%)	2 (50.0%)		
M stage	M0	48	1 (2.1%)	13 (27.1%)	34 (70.8%)	1	1
	M1	0	0 (0%)	0 (0%)	0 (0%)		
	Unknown	4	0 (0%)	2 (50.0%)	2 (50.0%)		
TNM stage	I-III	32	1 (3.1%)	7 (2.2%)	24 (75.0%)	0.317	0.545
	IV	16	0 (0%)	6 (37.5%)	10 (62.5%)		
	Unknown	4	0 (0%)	2 (50.0%)	2 (50.0%)		
Differentiation	Well	36	0 (0%)	9 (25.0%)	27 (75.0%)	0.674	0.131
	Moderate	12	0 (0%)	5 (41.7%)	7 (58.3%)		
	Poor	4	1 (25.0%)	1 (25.0%)	2 (50.0%)		
Mode of invasion	Grade 1	2	0 (0%)	1 (50.0%)	1 (50.0%)	0.683	0.708
	Grade 2	9	0 (0%)	2 (22.2%)	7 (77.8%)		
	Grade 3	21	0 (0%)	5 (23.8%)	16 (76.2%)		
	Grade 4C	16	1 (6.3%)	5 (31.3%)	10 (62.5%)		
	Grade 4D	4	0 (0%)	2 (50.0%)	2 (50.0%)		
S-LI grade	Grade 1	16	1 (6.3%)	4 (25.0%)	11 (68.7%)	0.749	0.879
	Grade 2	27	0 (0%)	8 (29.6%)	19 (70.1%)		
	Grade 3	9	0 (0%)	3 (33.3%)	6 (66.7%)		

P-value(a): for comparison between expression and high expression; P-value(b): for comparison between negative, expression, and high expression

Unknown cases (Tx, Nx, Mx, TNM) were excluded from statistical analysis



expression, a value which falls within the 42-80% range previously reported.<sup>8,12</sup> In one study of head and neck squamous cell carcinoma, a stronger intensity of EGFR staining was associated with a greater extent of EGFR expression.<sup>6</sup> However, our study failed to identify a significant correlation between extent score and intensity score.

EGF receptors initiate cytoplasmic signaling through autophosphorylation of their intracellular domains.<sup>13</sup> However, few studies have reported on p-EGFR expression in squamous cell carcinomas. One study of non-small cell lung cancer patients reported a 44.4% positive p-EGFR staining rate and a correlation between positivity and a shorter time to progression and a poorer prognosis.<sup>14</sup> Phosphorylated EGFR cytoplasmic tyrosine residues initiate the mitogen-activated protein kinase (MAPK) pathway.<sup>15</sup> This pathway culminates in activation and nuclear translocation of extracellular signal-regulated kinases (ERK 1 and 2) and in transcription of their target genes.<sup>16</sup> Preclinical studies have confirmed that interruption of EGFR phosphorylation can inhibit these downstream activation events, leading to cell cycle arrest and compromising tumor growth.<sup>17,18</sup> In our study, the rate of high p-EGFR expression was 69.2%.

EGFR is believed to influence important steps associated with tumor invasion and dissemination, including enhancement of cell motility, cytoskeletal changes, and production of extracellular matrix-degrading enzymes.<sup>19</sup> Several studies have reported that high EGFR expression in squamous cell carcinoma was associated with advanced tumor stage, lymph node metastasis, distant metastasis, differentiation, and invasion.<sup>14,20-22</sup> In our study, we observed a statistically significant correlation between high EGFR expression and diffuse invasion (as defined by the classification by Yamamoto et al) ( $P=0.047$ ). No significant correlation was identified between high EGFR or p-EGFR expression and tumor stage, lymph node metastasis, distant metastasis, or differentiation.

One published study reported that almost all cells were positive for EGFR in poorly differentiated squamous cell carcinomas of the head and neck region, and that sections from moderately- and well-differentiated tumors demonstrated a reduction in the extent of stained areas, paralleling the situation observed in the differentiated upper layers of normal oral and laryngeal mucosa.<sup>22</sup> In our study, we observed no significant correlation between high EGFR or p-EGFR expression and differentiation.

In conclusion, this study of oral and maxillofacial squamous cell carcinomas from the Department of Oral and Maxillofacial Surgery, Wakayama Medical University Hospital found that the majority of these tumors expressed EGFR or p-EGFR. High expression of EGFR or p-EGFR did not correlate with clinical factors. However, the mean overall score for p-EGFR was 3.67, a score slightly higher than the mean overall score of 3.42 for EGFR. Furthermore, we identified a statistically significant correlation between

high EGFR expression and the pathologic factor tumor invasion. These results indicate that EGFR may represent a promising target for novel molecular cancer therapies.

## References

1. Salomon DS, Brandt R, Ciardiello F, Normanno N: Epidermal growth factor-related peptides and their receptors in human malignancies. *Crit Rev Oncol Hematol* 19: 183-232, 1995
2. Mendelsohn J, Baselga L: Status of epidermal growth factor receptor antagonists in the biology and treatment of cancer. *J Clin Oncol* 14: 2787-2799, 2003
3. Irish JC, Bernstein A: Oncogenes in head and neck cancer. *Laryngoscope* 103: 42-52, 1993
4. Yamamoto E, Kohama G, Iwai M, Hiratsuka H: Mode of invasion, Bleomycin sensitivity and clinical course in squamous cell carcinoma of the oral cavity. *Cancer* 51: 2175-2180, 1983
5. Wada T: Nature of mononuclear cell infiltrates in oral squamous cell carcinoma and their clinical significance. *Wakayama Med Rep* 30: 103-117, 1989
6. Putti TC, To KF, Hsu HC, et al: Expression of epidermal growth factor receptor in head and neck cancers correlates with clinical progression: a multicentre immunohistochemical study in the Asia-Pacific region. *Histopathology* 41: 144-151, 2002
7. van Oijen MG, Rijkse G, ten Broek FW, Slootweg PJ: Increased expression of epidermal growth factor receptor in normal epithelium adjacent to head and neck carcinomas independent of tobacco and alcohol abuse. *Oral Dis* 4: 4-8, 1998
8. Wen QH, Nishimura T, Nagayama I, Furukawa M: Expression of EGF, EGFR and PCNA in laryngeal lesions. *J Laryngol Otol* 109: 630-636, 1995
9. Lee CS, Redshaw A, Boag G: Epidermal growth factor immunoreactivity in human laryngeal squamous cell carcinoma. *Pathology* 29: 251-254, 1997
10. Kearsley JH, Leonard JH, Walsh MD, Wright GR: A comparison of epidermal growth factor receptor (EGFR) and c-erbB-2 oncogene expression in head and neck squamous cell carcinomas. *Pathology* 23: 189-194, 1991
11. Zheng X, Hu L, Chen F, Christensson B: Expression of Ki67 antigen, epidermal growth factor receptor and Epstein-Barr virus-encoded latent membrane protein (LMP1) in nasopharyngeal carcinoma. *Eur J Cancer B Oral Oncol* 30: 290-295, 1994
12. Miyaguchi M, Olofsson J, Hellquist HB: Expression of epidermal growth factor receptor in glottic carcinoma and its relation to recurrence after radiotherapy. *Clin Otolaryngol* 16: 466-469, 1991
13. Downward J, Parker P, Waterfield MD: Autophosphorylation sites on the epidermal growth factor receptor. *Nature* 311: 483-485, 1984
14. Kanematsu T, Yano S, Uehara H, et al: Phosphorylation, but not overexpression, of epidermal growth factor receptor is associated with poor prognosis of non-small cell lung cancer patients. *Oncol Res* 13: 289-298, 2003
15. Olayioye MA, Neve RM, Lane HA, Hynes NE: The ErbB signaling network: Receptor heterodimerization in development and cancer. *EMBO J* 19: 3159-3167, 2000
16. Kolch W: Meaningful relationships: The regulation of the Ras/Raf/MEK/ERK pathway by protein interactions. *Biochem J* 351: 289-305, 2000
17. Zwick E, Bange J, Ullrich A: Receptor tyrosine kinases as targets for anti-cancer drugs. *Trends Mol Med* 8: 17-23, 2002
18. Busse D, Doughty RS, Ramsey TT, et al: Reversible G<sub>1</sub> arrest induced by inhibition of the epidermal growth factor receptor tyrosine kinase requires up-regulation of p27<sup>KIP1</sup> independent of MAPK activity. *J Biol Chem* 275: 6987-6995, 2000
19. Khazaie K, Schirrmacher V, Lichtner RB: EGF receptor in neoplasia and metastasis. *Cancer Metastasis Rev* 12: 255-274, 1993
20. Storkel S, Reichert T, Reiffen KA, Wagner W: EGFR and PCNA expression in oral squamous cell carcinomas—a valuable tool in estimating the patient's prognosis. *Eur J Cancer B Oral Oncol* 29: 273-277, 1993
21. Xia W, Lau YK, Zhang HZ, et al: Combination of EGFR, HER-2/neu, and HER-3 is a stronger predictor for the outcome of oral squamous cell carcinoma than any individual family members. *Clin Cancer Res* 5: 4164-4174, 1999
22. Christensen ME: The EGF receptor system in head and neck carcinomas and normal tissues. Immunohistochemical and quantitative studies. *Dan Med Bull* 45:121-134, 1998