

ARTICLE

Periacinar Clefting and p63 Immunostaining in Prostatic Intraepithelial Neoplasia and Prostatic Carcinoma

Božo KRUŠLIN, Davor TOMAS,¹Aida CVIKO, Hrvoje ČUPIĆ, Ljubica ODAK, Mladen BELICZA

Ljudevit Jurak Department of Pathology, Sestre milosrdnice University Hospital, Zagreb, Croatia, ¹Department of Pathology, Brigham and Women's Hospital, Harvard Medical School, Boston, USA

The aim of the present study was to correlate the presence and extent of retraction clefting and the expression of p63 in neoplastic glands and glands with prostatic intraepithelial neoplasia (PIN) in needle core biopsies. We analyzed needle core biopsies from 28 patients with PIN and 41 patients with adenocarcinoma. Neoplastic glands and those with PIN were analyzed on high power field (400x) and classified in three groups according to the extent of clefting. Immunohistochemical staining was performed following Microwave Streptavidin ImmunoPeroxidase (MSIP) protocol on DAKO TechMate Horizon automated immunostainer. Periacinar retraction clefting was significantly more prominent in prostat-

ic carcinoma compared to PIN ($p < 0.0001$) and non-neoplastic glands ($p < 0.0001$). There was no difference between normal glands and PIN regarding clefting ($p = 0.8064$). p63 was positive around the whole circumference in 12 out of 28 cases with PIN, and discontinuously positive in remaining 16 PIN cases suggesting initial disruption of the basal cell layer. p63 immunostaining was also positive in all nonneoplastic glands, and negative in all carcinomas. We conclude that retraction clefting was associated with cancer and lack of basal cells, but not with PIN. The relationship between clefting and p63 immunostaining in prostatic cancer should be further analyzed. (Pathology Oncology Research Vol 12, No 4, 205–209)

Key words: p63, periacinar clefting, prostatic adenocarcinoma, prostatic intraepithelial neoplasia (PIN)

Introduction

The diagnosis of prostatic carcinoma is based on three major histologic criteria; the infiltrative growth pattern, the absence of a basal cell layer and the presence of macronucleoli.^{1,5} The ability of immunohistochemical staining to detect basal cells has proven to be diagnostically invaluable, especially in needle biopsy specimens. p63, a homologue of the tumor suppressor gene p53, has been shown in the basal cell component of epithelium from a variety of tissues, including prostatic epithelium.^{16,20,25} Value of p63 immunostaining in the diagnosis of prostatic adenocarcinoma has been clearly shown.²⁵

Prostatic intraepithelial neoplasia (PIN) is the most likely precursor of prostatic adenocarcinoma according to

available data from the literature.^{1,14,19} PIN is the abnormal proliferation within the prostate ducts, ductules and large acini of premalignant foci of cellular dysplasia and carcinoma in situ without stromal invasion.^{1,14,19} The basal cell layer and basement membrane are preserved, however, focal disruption of the basal cell layer may be observed.¹⁹ The incidence of PIN varies according to the type of biopsied material. PIN is associated with progressive abnormalities of phenotype and genotype.^{2,19}

One of the criteria favoring prostatic adenocarcinoma is the presence of retraction clefting around neoplastic glands.^{11,12,24} The neoplastic cells of prostatic cancer often appear pulled away from the surrounding stroma leaving retraction artifacts around the acini.^{8,9} These retraction artifacts, periacinar halos or so-called retraction clefting are often observed, especially in Gleason pattern 3 prostatic carcinomas. It was shown that periacinar retraction clefting represents a reliable criterion for diagnosis of prostatic adenocarcinoma in needle core biopsies, especially in cases with clefts affecting more than 50% of circumference in at least 50% of suspicious glands.^{11,12} A correlation

Received: March 20, 2006; *accepted:* Oct 21, 2006

Correspondence: Božo KRUŠLIN, MD, PhD, Ljudevit Jurak Department of Pathology, Sestre milosrdnice University Hospital, Vinogradska 29., 10000 Zagreb, Croatia. Tel: 3851 3787 177, fax: 3851 3787 244, e-mail: bkruslin@kbsm.hr

of periacinar retraction clefting between needle core and corresponding prostatectomy specimens was found and therefore confirmed clefting as the criterion for diagnosis of prostatic adenocarcinoma.¹² It was suggested that this phenomenon is probably connected to the lack of basal cells. To analyze further this idea the study was aimed to correlate the presence and extent of retraction clefting and the expression of p63 in neoplastic glands and glands with prostatic intraepithelial neoplasia in needle core biopsies.

Material and Methods

Thirty-seven consecutive cases with high-grade intraepithelial neoplasia and 56 cases with prostatic carcinoma diagnosed during one year on the basis of major and favoring criteria at the Department of Pathology Sestre milosrdnice University Hospital, Zagreb, Croatia were chosen for the study. The patients underwent prostatic needle core biopsy after having an increased PSA serum value. The urologists pulled needle core biopsies from different areas of the prostate into 6 to 12 parts, usually maintaining orientation of the side and the part of prostate where biopsies were taken. An improved preembedding method was applied. Before fixation biopsy specimens were stretched and placed in tissue cassettes between two nylon meshes by the urologist immediately after biopsy. The tissue cassettes were immersed in containers filled with 10% buffered formaldehyde.^{17,18}

On the hematoxylin and eosin stained slides, all chosen tumors consisted of at least 30 or more neoplastic glands and in nontumorous part of specimens there were at least 30 or more nonneoplastic glands. After immunohistochemical procedure fifteen cases were excluded from the study because in deeper sections did not contain sufficient number of glands for observation (minimally 30 neoplastic and nonneoplastic glands). The same problem with deeper sections was observed in 9 cases with PIN that were also excluded from the study. There were 28 PIN cases with one to three glands (mean 1.28) in patients ranging in age from 53 to 84 years (mean 65.8 years) with PSA values of 4.2-121 ng/ml.

The study included forty-one patients with carcinoma who ranged in age from 53-82 years (mean 68.1 years). PSA value ranged from 4.2 to 381 ng/ml. Specimens were fixed in 10% buffered formaldehyde, embedded in paraffin, cut at 5 μ m thickness and routinely stained with hematoxylin and eosin. In some cases material was stained for high-molecular-weight cytokeratin and with alcian-PAS. Alcian-PAS positive staining was not used as the only criterion since it is well known that such positivity might be seen in mimickers of cancer such as atrophy and adenosis. Glands with PIN were analyzed on high power field (400x) and classified in three groups as follows: group I with no clefting, group II with clefting affecting up to 50% of

gland circumference, and group III with clefts affecting more than 50% of gland circumference. Clefting in neoplastic and nonneoplastic specimens were analyzed on 10 neoplastic and 10 normal glands in three different high power fields. Neoplastic and nonneoplastic glands were also classified in three groups: group I with no clefting or no clefts affecting more than 50% of circumference of glands, group II with up to 50% of glands (up to fifteen out of thirty) showing clefting that affected more than 50% of circumference, and group III with retraction clefting affecting more than 50% of circumference in 50% or more glands (fifteen or more out of thirty). Clefting at the edges of a biopsy and cleft-like spaces in glands with incomplete circumference were excluded from the examination, as at least some of them are likely to be a consequence of sectioning. Immunohistochemical staining was performed following Microwave Streptavidin ImmunoPeroxidase (MSIP) protocol on DAKO TechMate Horizon automated immunostainer using antibodies to p63 (4A4, M7247, DAKO, Glostrup, Denmark). As a control we used normal glands within the same biopsy.

Statistical analysis was performed using χ^2 test. The level of significance was set at 0.05.

Results

In glands with prostatic intraepithelial neoplasia clefts affecting more than 50% of gland circumference were not found. There were 5 PIN cases with clefting affecting less than 50% of circumference (group II) and 23 cases with no clefting (group I) (*Table 1*). In 22 cases PIN was associated with invasive carcinoma that was found in the same biopsy specimen. Prostatic carcinoma was found in 7 cases in the same cores, and in 15 cases in other cores of the same biopsy.

The most common Gleason pattern observed in carcinomas was 3 (40 out of 41 cases). Twenty-two tumors were of Gleason score 5 and 6, 18 Gleason score 7 and 1 Gleason score 8 (*Table 2*). Retraction clefting affecting more than 50% of circumference was observed in 37 of 41 neoplastic and 5 of 41 analyzed nontumorous samples. Sixteen neoplastic and none of nonneoplastic samples had 50% or more glands with clefts that affected more than 50% of gland circumference (*Table 1*). This difference was statistically significant ($p < 0.0001$). There was a statistically significant difference in the frequency and degree of clefting in tumorous glands in comparison with PIN ($p < 0.0001$). However, there was no difference between normal glands and PIN regarding clefting ($p = 0.8064$). In 21 tumorous and 5 nontumorous samples, clefts affecting more than 50% of circumference were observed but affected less than fifteen glands. Four neoplastic and 36 nonneoplastic samples were without clefts or with clefts affecting less than 50% of gland circumference (*Table 1*). Only basal cells were

Table 1. Distribution of periacinar retraction clefting in the glands with intraepithelial neoplasia, neoplastic and nonneoplastic glands

	<i>Prostatic intraepithelial neoplasia* number of cases (%)</i>	<i>Malignant glands** number of cases (%)</i>	<i>Nontumorous glands** number of cases (%)</i>
Group I	23 (82.1%)	4 (9.8%)	36 (87.9%)
Group II	5 (17.9%)	21 (51.2%)	5 (12.1%)
Group III	0 (0%)	16 (39.0%)	0 (0%)
Total	28 (100%)	41 (100%)	41 (100%)

*group I: no clefting, group II: clefting affecting up to 50% of gland circumference, group III: clefts affecting more than 50% of gland circumference

**group I: glands without clefts or with clefts affecting less than 50% of circumference, group II: up to 50% (<15) of glands with clefts affecting more than 50% of circumference, group III: 50% (15) or more glands with clefts affecting more than 50% of circumference

stained by p63. p63 was positive around the whole circumference in 12 out of 28 cases with intraepithelial neoplasia, and discontinuously positive in the remaining 16 PIN cases suggesting initial disruption of the basal cell layer. p63 immunostaining was also positive in all non-neoplastic glands, and negative in all carcinomas (Table 1, Figure 1).

Discussion

As the accurate diagnosis of prostatic carcinoma in the needle core biopsies demands sophisticated approach, there are many diagnostic criteria that should be satisfied. Besides three major histologic criteria, there are three additional diagnostic features of prostatic cancer, including mucinous fibroplasia, glomerulations and perineural invasion that have not been identified in benign conditions.^{5,6,24} Varma et al²⁴ in their study on 250 needle biopsy specimens with prostatic carcinoma found mucinous fibroplasia in only 3 (2%) cases, glomerulations in 23 (15.3%) and perineural invasion in 33 (22%) of cases. There are many additional criteria like marginated and/or multiple nucleoli, intraluminal crystalloids, intraluminal amorphous eosinophilic material, and others that are used in routine needle core biopsy diagnostics.^{2,7,24} Nowadays, the pathol-

ogist is more often confronted with limited amounts of carcinoma on fine needle biopsy with an increased risk of confusion with benign conditions.^{5,7,13} In a series of 24 limited carcinoma cases reported by Leroy et al¹³, diagnostic features for carcinoma were very rarely seen. Perineural invasion was not observed, collagenous micronodules were seen in one case only and mucinous fibroplasia was not even mentioned.

One of the proposed supportive criteria is the so-called periacinar retraction clefting. Halpert et al^{8,9} were the first to briefly describe the clefts in autopsy studies in prostatic adenocarcinoma in the 1960's. Our previous studies suggest that periacinar clefting is not simply a technical artifact without significance but instead represents the consequence of processes that affected neoplastic acini and surrounding stroma.^{10-12,22} Standard laboratory procedure probably, in a certain way, assists in appearance of clefting but clefts appear more frequently and extensively around glands without basal cell layer or glands surrounded with tumorous stroma when compared to normal glands. In this way, clefting is visible around neoplastic glands and could serve as a reliable and helpful diagnostic criterion.

In practice, failure of staining for high-molecular-weight cytokeratin to demonstrate the presence of any basal cells within a collection of glands does not guarantee that those glands represent carcinoma. However, the presence of clearly identifiable basal cells in a gland or duct does preclude the diagnosis of carcinoma for that structure.²⁵ At least focal high-molecular-weight cytokeratin positivity was observed in 1.1% of 3198 prostatic carcinoma cases diagnosed on needle core biopsies.¹⁵ All cases were Gleason score 6 with a mean number of 36.9 neoplastic glands. High-grade PIN was present in 64% of these cases adjacent to prostatic carcinoma with a mean number of 1.36 glands.¹⁵

Antibodies against high-molecular-weight cytokeratin (clone 34betaE12) and p63 are frequently used basal cell markers to aid the diagnosis of prostatic carcinoma. Technical factors such as tissue fixation and antigen retrieval

Table 2. Distribution of Gleason score among 41 prostatic needle biopsies with prostatic adenocarcinoma

<i>Gleason pattern with scores</i>	<i>Number of cases</i>	<i>%</i>
5 (2+3)	5	12.2
5 (3+2)	6	14.7
6 (2+4)	1	2.4
6 (3+3)	10	24.4
7 (3+4)	11	26.8
7 (4+3)	7	17.1
8 (3+5)	1	2.4
Total	41	100

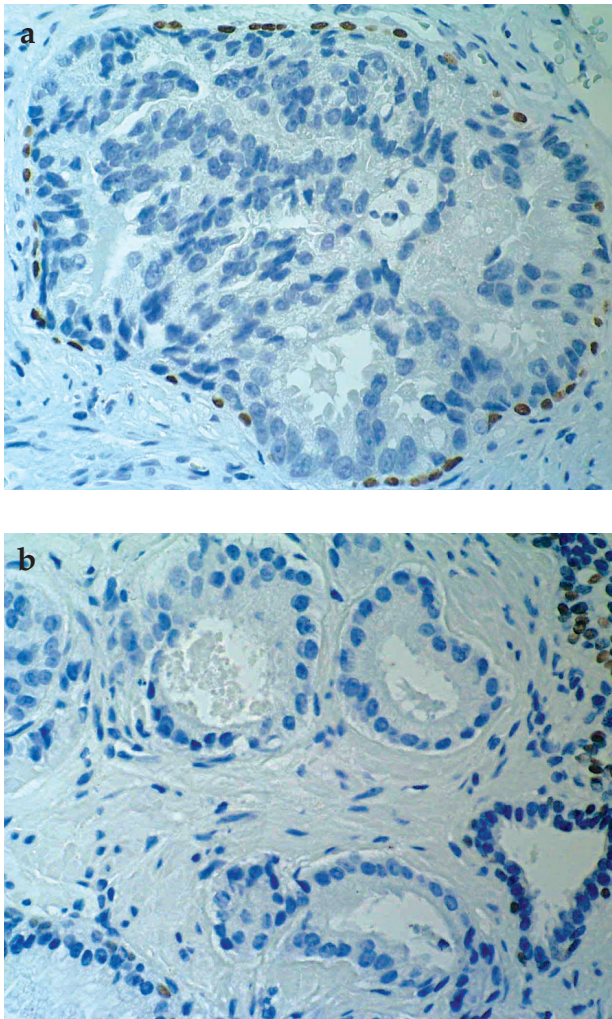


Figure 1. p63 immunostaining in prostatic intraepithelial neoplasia (a) and prostatic adenocarcinoma (b). Nonneoplastic glands served as a positive control (x400).

techniques may also make the detection of basal cells difficult.²⁶ Zhou et al²⁶ recommended this basal cell cocktail for routine prostatic carcinoma diagnostic work-up.

p63 is a recently introduced nuclear marker that may be useful for separating PIN and cancer from benign conditions mimicking cancer. Immunostaining of prostatic tissue, including benign glands, PIN and prostatic adenocarcinoma was restricted to basal cell nuclei.³ However, experience with p63 is limited to date and caution is urged owing to concerns with false-positive and false-negative staining.²

A new molecular marker called racemase or AMACR (alpha-methyl-acyl-CoA racemase, P504S) was recently applied to separate benign from neoplastic acini.^{2,4,23} However, a high proportion of high-grade PIN, as well as some foci of adenosis and some entirely benign glands are also positive for this marker.⁶

Because of the cytoplasmic localization of P504S and nuclear localization of p63, Tacha and Miller hypothesized that a cocktail of these two antibodies might allow simultaneous demonstration of P504S and p63 using a single immunostain.²¹ The authors concluded that this cocktail could be of great utility in the examination of diagnostically challenging prostate specimens.

Our results are strongly suggestive of a connection between the lack of basal cells in neoplastic glands and the development of retraction clefting. The results have also shown invariably negative staining for p63 in all carcinomas with periacinar retraction artifacts and positive staining in PIN cases. We conclude that clefting represent a reliable diagnostic criterion and that staining for p63 might be needed when retraction clefting affect less than 50% of circumference of glands or are not present. Determination of retraction clefting could be performed during the routine analysis of specimens under low magnification and the extent of clefting around particular glands under high magnification. This procedure does not significantly prolong time needed for routine biopsy evaluation.

The value of retraction clefting in the differential diagnosis between adenocarcinoma and mimickers of cancer, especially atrophy and postatrophic hyperplasia and adenosis, should be further analyzed.

References

1. Bostwick DG, Dundore PA: Biopsy pathology of the prostate. Chapman&Hall Medical, London, 1997.
2. Bostwick DG, Qian J: High-grade prostatic intraepithelial neoplasia. *Mod Pathol* 17: 360-379, 2004.
3. Davis LD, Zhang W, Merseburger A, et al: p63 expression profile in normal and malignant prostate epithelial cells. *Anti-cancer Res* 22: 3819-3825, 2002.
4. De Marzo AM, Meecker AK, Zha S, et al: Human cancer precursors and pathobiology. *Urology* 62(Suppl 1): 55-62, 2003.
5. Epstein JI: Diagnosis and reporting of limited adenocarcinoma of the prostate on needle biopsy. *Mod Pathol* 17: 307-315, 2004.
6. Epstein JI: Diagnosis and reporting of limited adenocarcinoma of the prostate on needle biopsy. *Pathol International* 54(Suppl 1): S609-S612, 2004.
7. Epstein JI: The diagnosis and reporting of adenocarcinoma of the prostate in core needle biopsy specimens. *Cancer* 78: 350-356, 1996.
8. Halpert B, Schmalhorst WR: Carcinoma of the prostate in patients 70 to 79 years old. *Cancer* 19: 695-698, 1966.
9. Halpert B, Sheehan EE, Schmalhorst WR, Scott R Jr: Carcinoma of the prostate: a survey of 5000 autopsies. *Cancer* 16: 736-742, 1963.
10. Kru lin B, Novosel I, Reljic A, et al: Periacinar cleft-like spaces in prostatic needle core biopsies. *Acta Clin Croat* 41: 175, 2002.
11. Kru lin B, Tomas D, Rogatsch H, et al: Periacinar retraction clefting in the prostate needle core biopsies: an important diagnostic criterion or a simple artifact? *Virchows Arch* 443: 524-527, 2003.
12. Kru lin B, Tomas D, Rogatsch H, et al: Correlation of periacinar retraction clefting in needle core biopsies and corresponding prostatectomy specimens of patients with prostatic adenocarcinoma. *Int J Surg Pathol* 13: 67-72, 2005.

13. *Leroy X, Aubert S, Villers A, et al*: Minimal focus of adenocarcinoma on prostate biopsy: clinicopathologic correlations. *J Clin Pathol* 56: 23-32, 2003.
14. *McNeal JE, Bostwick DG*: Spread of adenocarcinoma within prostatic ducts and acini. Morphologic and clinical correlations. *Am J Surg Pathol* 20: 802-814, 1996.
15. *Oliai BR, Kahane H, Epstein JI*: Can basal cells be seen in adenocarcinoma of the prostate?: an immunohistochemical study using high molecular weight cytokeratin (clone 34 beta E12) antibody. *Am J Surg Pathol* 26: 1151-1160, 2002.
16. *Parsa R, Yang A, McKeon F, Green H*: Association of p63 with proliferative potential in normal and neoplastic human keratinocytes. *J Invest Dermatol* 113: 1099-1105, 1999.
17. *Rogatsch H, Mairinger T, Horninger W, et al*: Optimized pre-embedding method improves the histologic yield of prostatic core needle biopsies. *Prostate* 42: 124-129, 2000.
18. *Rogatsch H, Moser P, Volgger H, et al*: Diagnostic effect of an improved preembedding method of prostate needle biopsy specimens. *Hum Pathol* 31: 1102-1107, 2000.
19. *Sakr WA*: Prostatic intraepithelial neoplasia. *Pathol International* 54(Suppl 1):S612-S615, 2004.
20. *Signoretti S, Waltregny W, Dilks J, et al*: p63 is a prostate basal cell marker and is required for prostate development. *Am J Pathol* 157: 1769-1775, 2000.
21. *Tacha DE, Miller RT*: Use of p63/P504S monoclonal antibody cocktail in immunohistochemical staining of prostate tissue. *Appl Immunohistochem Mol Morphol* 12: 75-78, 2004.
22. *Tomas D, Kru lin B*: The potential value of (myo)fibroblastic stromal reaction in the diagnosis of prostatic adenocarcinoma. *Prostate* 61: 324-331, 2004.
23. *Varma M, Jasani B*: Diagnostic utility of immunohistochemistry in morphologically difficult prostate cancer: review of current literature. *Histopathology* 47: 1-16, 2005.
24. *Varma M, Lee MW, Tamboli P, et al*: Morphologic criteria for the diagnosis of prostatic adenocarcinoma in needle biopsy specimens. *Arch Pathol Lab Med* 126: 554-561, 2002.
25. *Weinstein MA, Signoretti S, Loda M*: Diagnostic utility of immunohistochemical staining for p63, a sensitive marker of prostatic basal cells. *Mod Pathol* 15: 1302-1308, 2002.
26. *Zhou M, Shah R, Shen R, Rubin MA*: Basal cell cocktail (34betaE12 + p63) improves the detection of prostate basal cells. *Am J Surg Pathol* 27: 365-371, 2003.