

## CASE REPORT

## Metastatic Renal Clear Cell Carcinoma in the Parotid Gland: A Study of Immunohistochemical Profile and Cell Adhesion Molecules (CAMs) Expression in Two Cases

Dimitrios ANDREADIS, Alexandros NOMIKOS, Calypso BARBATIS

Department of Histopathology, Hellenic Red Cross Hospital of Athens, Athens, Greece

Metastasis of renal cell carcinoma (RCC) may involve any organ, including the parotid salivary gland. While the definition of salivary gland neoplasms with clear cell transformation can be concluded by the synchronous presence of areas showing typical morphology, sometimes the definition of a metastatic RCC in the parotid is difficult and the application of immunohistochemistry may support the clinical and radiographic observations in

the final diagnosis. The aim of this paper was to describe the heterogeneous immunohistochemical features and, furthermore, to characterize the pattern of expression of cell adhesion molecules (CAMs) E-cadherin,  $\beta$ 4-integrin, desmoglein-2, ICAM-1 and CD44s (HCAM) in two cases of metastatic parotid RCC. (Pathology Oncology Research Vol 13, No 2, 161–165)

*Key words:* metastatic renal cell carcinoma, parotid gland, cell adhesion molecules, immunohistochemistry

### Introduction

Clear cell neoplasms of the maxillofacial area can represent salivary gland neoplasms, odontogenic or metastatic tumors.<sup>1</sup> The majority of metastatic tumors in the parotid gland are carcinomas and melanomas of the head and neck, but a number of them may be originated from the urogenital tract, such as renal cell carcinoma (RCC).<sup>2</sup> Although the most common sites for RCC metastasis are the lung, lymph nodes, bone, liver, adrenal and brain, this neoplasm may involve any organ including the parotid as an unusual metastatic site.<sup>3,4</sup> Because of the high vascularity of kidneys, hematogenous dissemination is thought to be the way through which RCC metastasizes in the parotid gland involving interlobular and intralobular fibrous septa and extending into the parenchyma only secondarily.<sup>5,6</sup> Noteworthy, this parotid involvement in certain cases may be the first indication of a pre-existing primary RCC.<sup>7</sup>

While the definition of salivary gland neoplasms with clear cell transformation can be concluded by the synchronous

presence of areas showing typical morphology, the differential diagnosis between metastatic RCC or other metastatic tumors and mainly the primary clear cell adenocarcinoma not otherwise specified (CCANOS) of the salivary gland is problematic or even impossible by pathological studies alone.<sup>1,8</sup>

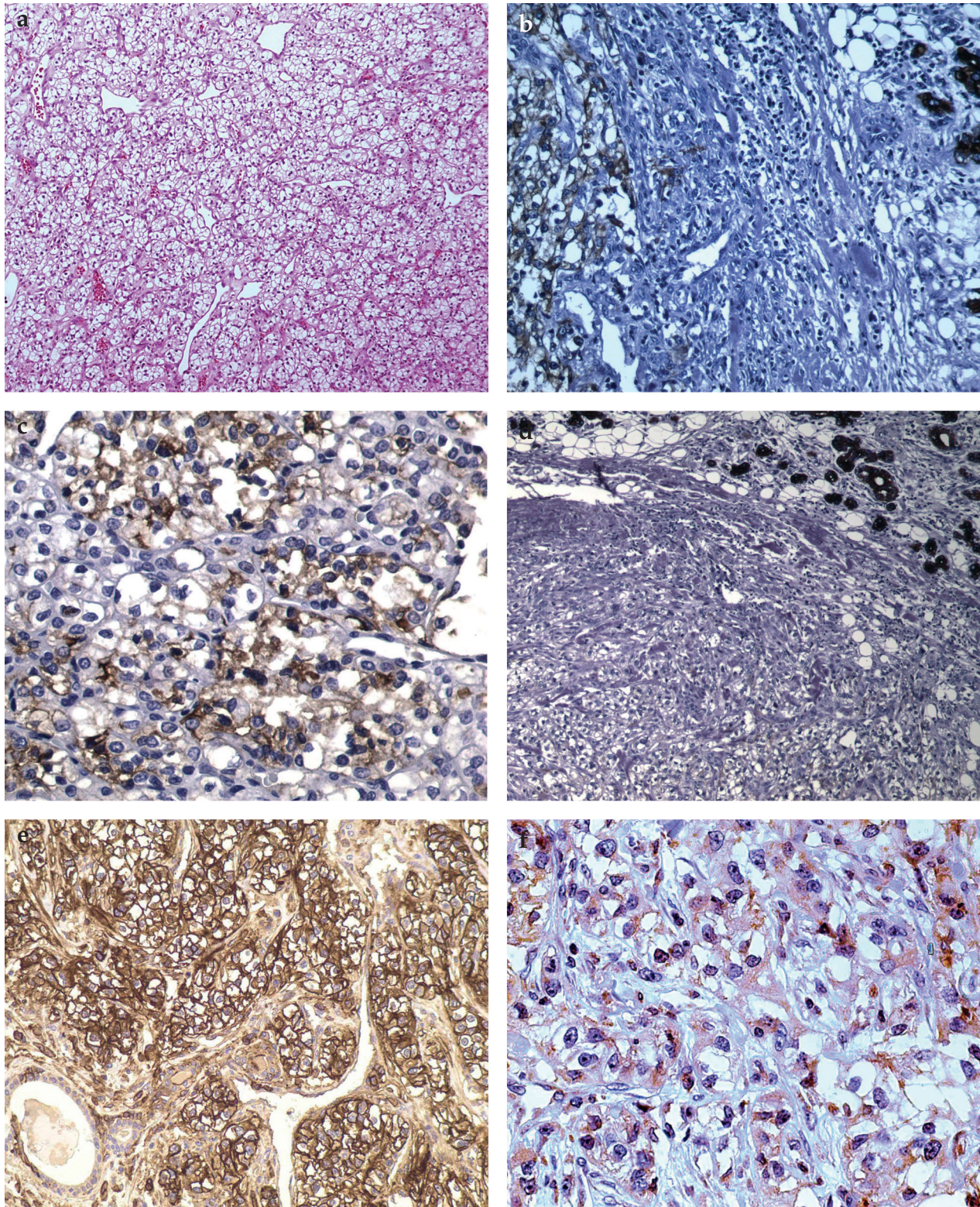
The aim of this paper was to describe the findings of immunohistochemistry and, furthermore, to characterize the pattern of expression of cell adhesion molecules (CAMs) E-cadherin,  $\beta$ 4-integrin, desmoglein-2, ICAM-1 and CD44s (HCAM), which participate in cell-cell and cell-stroma interactions in two metastatic RCCs in the parotid gland.

### Cases

The study of the two metastatic renal clear cell carcinomas was based on the findings of histochemical and immunohistochemical markers and additionally of antibodies against CAMs E-cadherin,  $\beta$ 4-integrin, desmoglein-2, ICAM-1 and CD44s (HCAM) (all from Santa Cruz Biotechnology Inc, Santa Cruz, CA, USA), using an automated Envision/HRP technique (DakoCytomation A/S, Glostrup, Denmark) on formalin-fixed, paraffin-embedded sections. Staining was scored as follows: – (negative) for up to 2%, + (weak) for up to 25%, ++ (moderate) for up to 50% and +++ (strong) for more than 50% positive neoplastic cells.

*Received:* Oct 30, 2006; *accepted:* March 20, 2007

*Correspondence:* Dimitrios ANDREADIS, DDS, PhD, Department of Histopathology, Red Cross Hospital of Athens, Greece. 4 Sarantaporou St, 155-61, Athens, Greece. Tel: +302108014928, fax: +302104836883, e-mail: uromorulin@hotmail.com



**Figure 1.** Case 1. (a) Hematoxylin-eosin staining. Monomorphic population of polygonal to round cells with well-demarcated contours and optically clear cytoplasm, with a large number of vessels. (b) Strong positive staining for CK 19 (c) Clear cells immunoreactive for CD10. (d) Absence of staining for CK 7. Note the expression of the ductal cells of non-tumorous adjacent parotid tissue. (e) Strong membrane immunoreactivity for ICAM-1. Note the weak positivity of the normal ductal epithelium. (f) Focal cytoplasmic expression of  $\beta$ 4-integrin

### Case 1

The first case was a metastatic RCC in the parotid of a patient with a known history of primary RCC in the left kidney. Histologically, the parotid tumor was composed of trabeculae, cords, nests, solid sheets of a monomorphous population of polygonal to round cells with well demarcated contours and optically clear cytoplasm, when stained with hematoxylin-eosin. In addition, there was a portion of cells presenting pale eosinophilic cytoplasm. Neoplastic cells had rounded, eccentric, lightly basophilic nuclei, frequently containing small nucleoli. Ductal structures and mitotic figures were scanty or absent. The neoplastic cells were arranged in a highly vascular but not hyalinized stroma (*Fig. 1a*), without any synchronous presence of areas showing typical morphology for other salivary gland neoplasm. The results of immunohistochemistry are summarized in *Table 1*. Ki67 was immunoreactive in up to 5% of the neoplastic cells. Strong or moderate expression for cytokeratins (CK) 8 and 19 (*Fig. 1b*), CD10 (*Fig. 1c*), S-100 protein, EMA and vimentin, but not for CKs 34  $\beta$ E12 (high-molecular-weight cytokeratins 1, 5, 10, 14), 7 and 18 was observed (*Fig. 1d*). In this case, in the adjacent non-tumorous parotid parenchyma E-cadherin and desmoglein-2 exhibited a similar pattern of expression located in cell-cell contacts, being increased from acinar to ductal epithelium.  $\beta$ 4-integrin and HCAM (CD44s) were both present in the overall membrane of acinar cells. Interestingly,  $\beta$ 4-integrin

was also expressed at the membrane of basal ductal cells, whereas HCAM (CD44s) was decreased located only in basolateral portions of basal ductal cells. In the stroma, anti- $\beta$ 4-integrin antibody stained the endothelium, whereas anti-HCAM (CD44s) labeled lymphocytes and macrophages, respectively. On the other hand, neoplastic clear cells were strongly membrane-stained for ICAM-1 and E-cadherin (*Fig. 1e*), in contrast to the weak cytoplasmic expression of  $\beta$ 4-integrin (*Fig. 1f*), and the negative staining for desmoglein-2 and CD44s (HCAM).

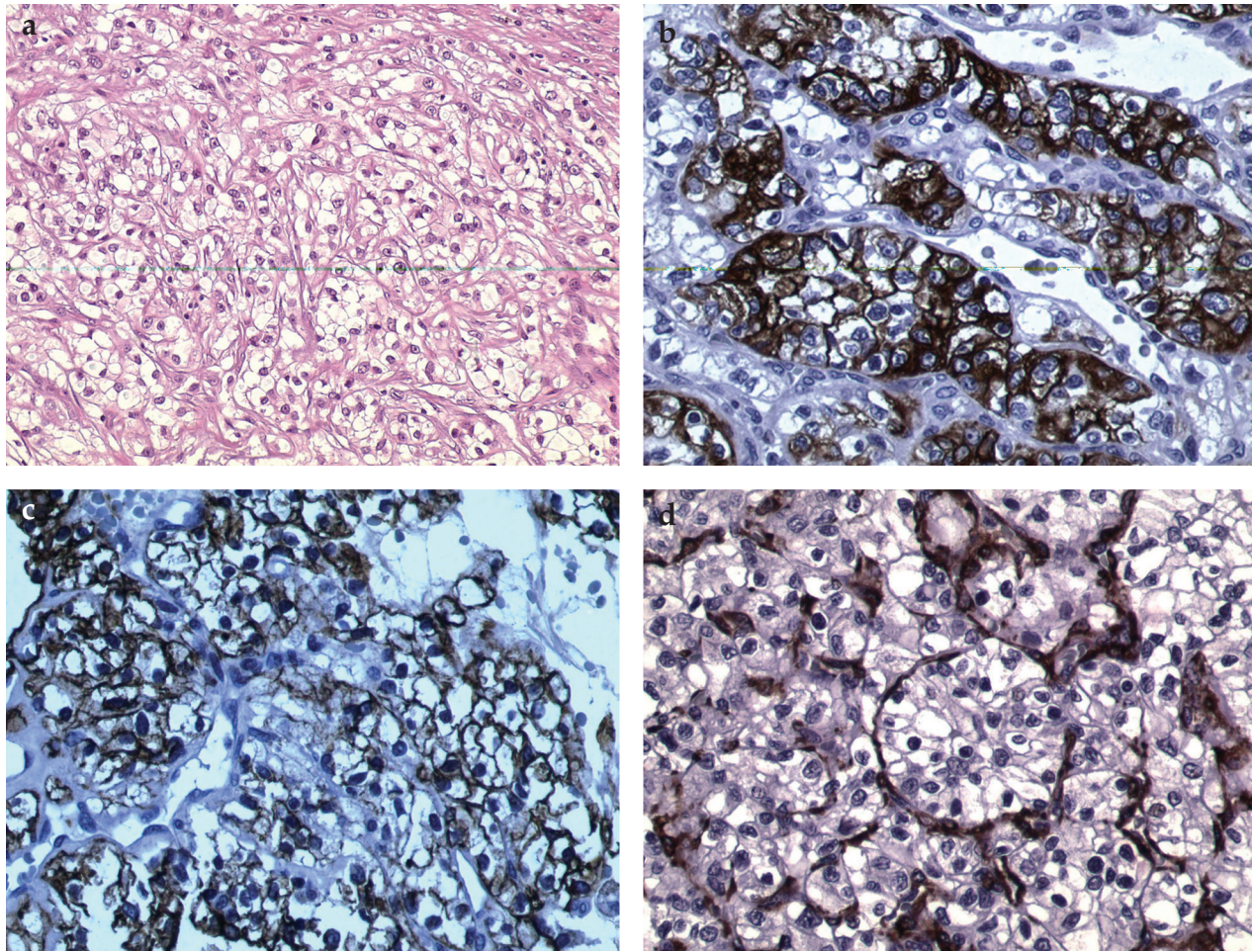
### Case 2

The second case was a parotid clear cell tumor of a patient with a history of a kidney removal 10 years ago (for unknown reason). This neoplasm was also composed of trabeculae, cords, nests, solid sheets of a monomorphous clear cell population, when stained with hematoxylin-eosin and, additionally, there was a portion of pale eosinophilic cells. Neoplastic cells had round, eccentric, lightly basophilic nuclei, frequently containing small nucleoli and were weakly to moderately stained with PAS [PAS-diacetate (-), Sudan Black (-)]. Ductal structures and mitotic figures were scarce or absent and the neoplastic population was arranged in a variably (but not excessively) hyalinized stroma, with numerous of vessels (*Fig. 2a*). There was no synchronous presence of areas showing typical morphology for other salivary gland neoplasm. The results of immunohistochemistry

**Table 1. Results of immunohistochemistry**

Antibody	Source/dilution	Case 1	Case 2
CD10	Mouse, 1:50	++	++
Ki67	Mouse, 1:150	Up to 5%	Up to 2%
34 $\beta$ E12 (CKs 1, 5, 10, 14)	Mouse, 1:50	-	-
P53	Mouse, 1:50	n.e.	Up to 2%
CK19	Mouse, 1:100	+++	+++
EMA	Mouse, 1:100	++	++
ICAM-1	Mouse, 1:100	+++	+++
E-cadherin	Mouse, 1:100	+++	+++
$\beta$ 4-integrin	Rabbit, 1:200	+	+
Desmoglein-2	Rabbit, 1:200	-	-
CD44s(HCAM)	Mouse, 1:100	-	-
CK7	Mouse, 1:100	-	+++
CK8	Mouse, 1:100	+	+++
CK18	Mouse, 1:50	-	+++
S-100	Rabbit, 1:100	+++	-
aSMA	Mouse, 1:100	n.e.	- (+ endothelium and stromal cells)
Vimentin	Mouse, 1:100	+++	- (+ endothelium and stromal cells)
Bcl-2	Mouse, 1:100	n.e.	+++
C-KIT (CD117)	Rabbit, 1:400	n.e.	-
Synaptophysin	Rabbit, 1:100	n.e.	-
NSE	Mouse, 1:200	n.e.	+
Chromogranin	Mouse, 1:200	n.e.	-

\*CK: cytokeratin, NSE: neuron-specific enolase, SMA: smooth muscle actin, n.e.: not evaluated



**Figure 2.** Case 2. (a) Hematoxylin-eosin staining. Monomorphic clear cell population arranged in a variably but not excessively hyalinized stroma with numerous blood vessels. (b) Strong positivity for CK 7. (c) Moderate positivity for EMA. (d) aSMA expression at the stromal non-neoplastic cells

are summarized in *Table 1*. Ki67 and p53 were immunoreactive in up to 2% of the cells using digital image analysis system, in selected high-power fields. Noteworthy, neoplastic clear cells were strongly positive for CKs 7 (*Fig. 2b*), 8, 18 and 19, CD10, NSE and Bcl-2, and moderately positive for EMA (*Fig. 2c*). On the other hand, aSMA (*Fig. 2d*) and vimentin were stained only in the endothelium and the stromal non-neoplastic cells, and the neoplastic cells were also negative for chromogranin and synaptophysin. In this case ICAM-1 and E-cadherin were also positive, in contrast to the weak cytoplasmic expression of  $\beta$ 4-integrin, and the negative staining for desmoglein-2 and CD44s (HCAM).

### Discussion

The clear cell phenotype may generally result from artifacts in fixation, or may represent peculiar functional states of the tumor cells. A scarcity of organelles in clear salivary ductal cells, glycogen storage in myoepithelial

cells, accumulation of mucins in mucous cells, lipids in sebaceous cells and immature zymogen granules in clear acinar cells also account for this appearance.<sup>1</sup> Clear cell transformation can occur in a variety of benign and malignant salivary gland neoplasms including pleomorphic adenoma, clear cell oncocytoma, sebaceous adenoma and carcinoma, mucoepidermoid carcinoma, acinic cell adenocarcinoma and epithelial-myoepithelial carcinoma.<sup>7</sup> It can also be the predominant morphological feature of secondary neoplasms originated from the kidney, thyroid, parathyroid, prostate, liver or lung.<sup>1,9</sup>

On the other hand, alternative expression of cell adhesion molecules (CAMs) is associated with pathogenesis and progression of benign and malignant neoplasms of various tissues.<sup>10</sup> E-cadherin<sup>11</sup> and desmoglein-2, the main desmoglein expressed in the desmosomal junctions of salivary gland epithelium,<sup>12</sup>  $\beta$ 4-integrin,  $\alpha$ 6 $\beta$ 4 laminin receptor of hemidesmosomes,<sup>13</sup> HCAM (CD44s) associated with hyaluronan<sup>14</sup> and ICAM-1,<sup>15</sup> member of Ig superfam-

ily, are mainly implicated in normal tissue epithelial architecture and/or immune responses.

The distinction of metastatic RCC from primary salivary CCANOS and other salivary gland tumors with clear cell transformation is important because of prognostic and therapeutic implications. The synchronous presence of typical features for a salivary gland tumor may help the clarification of the diagnosis. On the other hand, although RCC exhibits high vascularity and necrotic areas, absence of tonofilaments, greater nuclear atypia, existence of cytoplasmic lipids in addition to glycogen and accumulations of basal lamina material,<sup>9</sup> it is not always possible to differentiate this tumor from a salivary gland CCANOS. Immunohistochemically, RCC has been shown to be consistently positive for CD10, low-molecular-weight cytokeratins and vimentin, and variably positive for EMA, RCC antibody (a monoclonal antibody, against a normal human proximal tubular brush border antigen) and CK 7,<sup>8,16,17</sup> whereas most primary salivary CCANOSs revealed focal to diffuse immunoreactivity for cytokeratins, EMA, CEA, but were negative for CD10, glial fibrillary acid protein (GFAP) and markers of myoepithelial differentiation (actin, calponin).<sup>1,18</sup> Although S-100 is generally considered to be negative, a number of salivary CCANOS cases show focal or, rarely, strong immunoreactivity to this protein.<sup>19</sup>

In our cases the immunohistochemical findings of epithelial and non-epithelial markers were not identical. Both of the cases revealed positivity for cytokeratin 19, EMA and CD10 and absence of staining for low-molecular-weight cytokeratins. Interestingly, both of the cases revealed characteristic immunoreactivity for CAMs. E-cadherin molecule, member of the epithelial adherent junctions and ICAM-1 activated immune receptor were strongly positive, while  $\beta$ 4-integrin showed focal cytoplasmic expression in this metastatic tumorous lesion, suggesting a participation in tissue rearrangement (E-cadherin) and tumor invasion ( $\beta$ 4-integrin and ICAM-1). On the other hand, Case 1, in contrast to Case 2, was negative for PAS staining and cytokeratins 7 and 18, and positive for S-100 and vimentin.

The histological appearance of the first case, including the high vascularity, the absence of hyalinized stroma and the positive staining for CD10 and EMA, combined with the previous history of the primary kidney RCC, were supportive of the diagnosis of RCC. In the second case, the lack of areas showing typical morphology of other salivary gland tumor, and the absence of staining with chromogranin or synaptophysin were not sufficient for any other salivary or metastatic clear cell tumor. Although the focal hyalinization of stroma, the weak to moderate PAS staining, the expression of CK 7 and the absence of staining with markers of myoepithelial differentiation such as vimentin and S-100 protein could suggest a diagnosis of a parotid CCANOS, the high vascularity of the stroma, the strong immunoreactivity of neoplastic cells for CD10, and secondarily for NSE and CK19, together with clinical and

radiographic information clarified the diagnosis of RCC metastatic to the parotid.

In conclusion, we have described two cases of metastatic RCC in the parotid with heterogeneous immunohistochemical profile. The combined application of immunohistochemical markers may be supportive of the diagnosis only when they accompany the clinical, radiographic and basic histological observations. Although both of our cases were positive for CD10, cytokeratin 19, and CAMs E-cadherin, ICAM-1 and  $\beta$ 4 integrin, further investigation in a large number of RCC cases is needed to confirm their reliability or to identify other specific markers to distinguish this tumor from other salivary clear cell neoplasms.

### References

1. *Maiorano E, Altini M, Favia G*: Clear cell tumors of the salivary glands, jaws, and oral mucosa. *Semin Diagn Pathol* 14:203-212, 1997
2. *Hessan H, Strauss M, Sharkey FE*: Urogenital tract carcinoma metastatic to the head and neck. *Laryngoscope* 96:1352-1356, 1986
3. *Adil G, Murat D, Ayhan O, Ozgur TM, Ibrahim Y, Fuat PA, Rifki F*: Renal cell carcinoma metastatic to the parotid gland. 83:861-862, 1999
4. Solitary metastasis of renal cell carcinoma to the parotid gland 10 years after radical nephrectomy. *Int J Urol* 11:894-896, 2004
5. Parotid gland metastasis from renal cell carcinoma. *Laryngoscope* 112:453-456, 2002
6. Clear cell tumors of salivary glands. *Ann Otol Rhinol Laryngol* 89:196-197, 1980
7. *Ellis GL, Auclair PL*: Tumors of the salivary glands. Washington DC: Armed Forces Institute of Pathology, 1996, pp 281-289
8. *Seijas BP, Franco FL, Sastre RM, Garcia AA, Cernanos JLL*: Metastatic renal cell carcinoma presenting as a parotid tumor. *Oral Surg Oral Med Oral Pathol Oral Radiol Endod* 99:554-557, 2005
9. *Nappi O, Mills SE, Swanson PE, Wick MR*: Clear cell tumors of unknown nature and origin: a systematic approach to diagnosis. *Semin Diagn Pathol* 14:203-212, 1997
10. *Albelda SM*: Biology of disease: Role of integrins and other cell adhesion molecules in tumor progression and metastasis. *Lab Invest* 68:4-17, 1993
11. *Pignatelli M, Vessey CJ*: Adhesion molecules: Novel molecular tools in tumor pathology. *Hum Pathol* 25:849-856, 1994
12. *Schafer S, Koch PJ, Franke WW*: Identification of the ubiquitous human desmoglein, Dsg2, and the expression catalogue of the desmoglein subfamily of desmosomal cadherins. *Exp Cell Res* 211:391-399, 1994
13. *Mercurio AM, Rabinovitz I*: Towards a mechanistic understanding of tumor invasion—lessons from the  $\alpha$ 4 $\beta$ 4 integrin. *Semin Cancer Biol* 11:129-141, 2001
14. *Sneath RJS, Mangham DC*: The normal structure and function of CD44 and its role in neoplasia. *J Clin Pathol: Mol Pathol* 51:191-200, 1998
15. *Thiery JP*: The Ig superfamily of adhesion molecules. In Kreis T, Vale R: *Guidebook extracellular matrix, anchor and adhesion proteins*. 2<sup>nd</sup> edition, Oxford University Press, 1999, pp 125-128
16. *Ozolek JA, Bastacky SI, Myers EN, Hunt JL*: Immunophenotypic comparison of salivary gland oncocytoma and metastatic renal cell carcinoma. *Laryngoscope* 115:1097-1100, 2005
17. *Rosai J*: *Rosai and Ackerman's Surgical Pathology*. Ninth Edition. Vol.1. Mosby, London, 2004
18. *Dabbs D*: *Diagnostic Immunohistochemistry*. Churchill Livingstone, New York, 2004
19. *Wang B, Brandwein M, Gordon R, Robinson R, Urken M, Zarbo RJ*: Primary salivary clear cell tumors—a diagnostic approach: a clinicopathologic and immunohistochemical study of 20 patients with clear cell carcinoma, clear cell myoepithelial carcinoma, and epithelial-myoeplithelial carcinoma. *Arch Pathol Lab Med* 126:676-685, 2002