

## CASE REPORT

## Primary Bone Marrow T-cell Anaplastic Large Cell Lymphoma with Triple M Gradient

Árpád SZOMOR,<sup>1</sup> Talal AL SAATI,<sup>4</sup> Georges DELSOL,<sup>4</sup> László KERESKAI,<sup>2</sup> Zsuzsanna SZIJÁRTÓ,<sup>3</sup>  
Hajna LOSONCZY<sup>1</sup>

<sup>1</sup>1<sup>st</sup> Department of Medicine, <sup>2</sup>Institute of Pathology, <sup>3</sup>Department of Ophthalmology, University of Pécs, Hungary;  
<sup>4</sup>Laboratory of Anatomic Pathology, Central Hospital University Purpan, Toulouse, France

We present a case of a 60-year-old male patient with primary bone marrow anaplastic large cell lymphoma. He was admitted to the hospital with the symptoms of anemia and fever. There was no evidence of lymphadenopathy or splenomegaly. Immunoelectrophoresis showed the presence of a triple M gradient (double IgM and an IgG), with the IgG and one of the IgM paraproteins functioning as a cryoglobulin. The patient had no hepatitis C virus infection. Bone marrow biopsy showed massive CD30-positive, ALK-negative large lymphoid cell infiltration of T-cell origin with anaplastic morphology. PCR analysis of lymphoid cells separated from the bone marrow demonstrated the presence of a B/T hybrid genotype disorder with no evidence of the t(2;5), nor t(1;2) translocations. The patient entered a period of remission following CHOP chemotherapy. The patient subsequently died of sepsis as a consequence of serious humoral immunodeficiency. (Pathology Oncology Research Vol 13, No 3, 260–262)

phoid cell infiltration of T-cell origin with anaplastic morphology. PCR analysis of lymphoid cells separated from the bone marrow demonstrated the presence of a B/T hybrid genotype disorder with no evidence of the t(2;5), nor t(1;2) translocations. The patient entered a period of remission following CHOP chemotherapy. The patient subsequently died of sepsis as a consequence of serious humoral immunodeficiency. (Pathology Oncology Research Vol 13, No 3, 260–262)

*Key words:* anaplastic large cell lymphoma, T-cell receptor gene rearrangement, immunoglobulin heavy chain gene rearrangement, M gradient, bone marrow

### Introduction

Anaplastic large cell lymphoma (ALCL) is a small, heterogeneous group of high-grade non Hodgkin's lymphomas, accounting for about 2-5% of all non Hodgkin's lymphomas. Recently three main subtypes of ALCL have been identified: primary systemic ALK-positive ALCL, primary systemic ALK-negative ALCL and primary cutaneous ALCL.<sup>1</sup> The most important histological signs of the lymph node in ALCL are the paracortical tumor cell

involvement, intrasinusoidal invasion and cohesive propagation of large, bizarre tumor cells with characteristic nucleoli.<sup>7</sup> Primary systemic ALCL (both ALK-positive and ALK-negative) generally involves extranodal sites in 50-60% of cases<sup>3,5,6,10</sup> while bone marrow involvement is observed in only about 0-17% of all ALCLs.<sup>3,5,6,8,10</sup> Thus, while primary bone marrow lymphoma is an infrequent event, the additional presence of the auto-immune phenomena, M gradient, as presented in this case study, is an extremely rare event in ALCL.

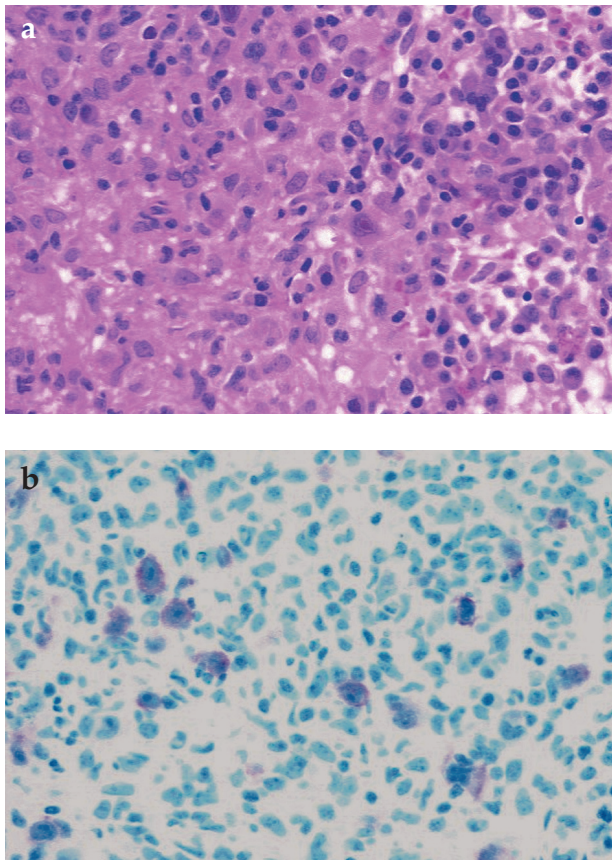
### Case report

A 60-year-old male patient was admitted to our hospital with the symptoms of anemia: retrosternal pain, dizziness, fatigue and weight loss. He had pancytopenia: severe normocytic, normochromic anemia (hgb:86 g/l), a white blood cell count of 1,5 G/l, with a platelet count of 105 G/l. The lactate dehydrogenase level was normal, but the  $\beta$ 2-microglobulin level was elevated (3.212 mg/l). Immunoelectrophoresis showed the presence of a triple M gradient (two IgM and one IgG paraprotein: 6.4

*Received:* Nov 15, 2006; *accepted:* July 15, 2007

*Correspondence:* Árpád SZOMOR, MD, PhD, 1st Department of Medicine, University of Pécs, Ifjúság u. 13., Pécs, H-7624, Hungary. Tel: 00-36-72-536000/1323, fax: 00-36-72-536148, E-mail: aszomor@clinics.pote.hu

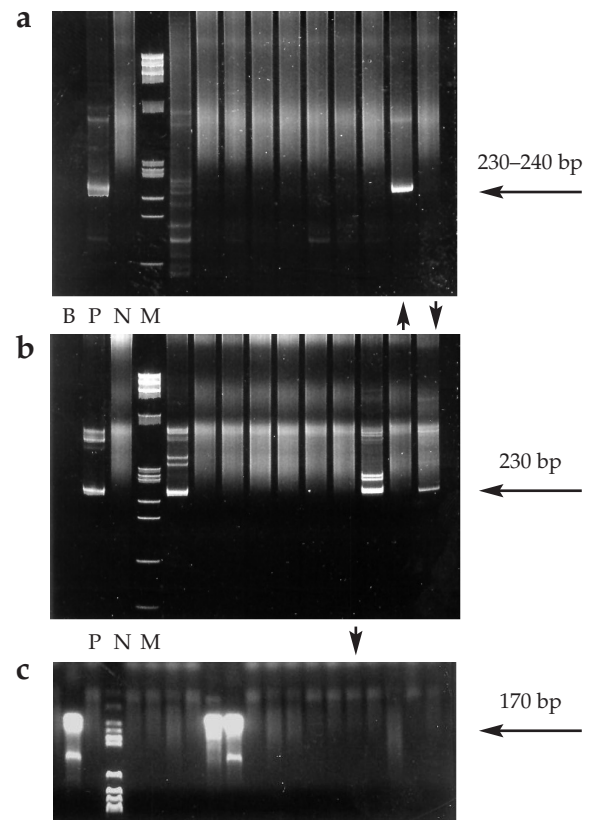
*Abbreviations:* PCR: polymerase chain reaction, IgH: immunoglobulin heavy chain, TCR: T-cell receptor, RT-PCR: reverse transcriptase polymerase chain reaction, ALK: anaplastic lymphoma kinase, CHOP: cyclophosphamide-hydroxy epirubicine-oncovin-prednisolone, ALCL: anaplastic large cell lymphoma, HCV: hepatitis C virus, HBsAg: hepatitis B surface antigen, MDR: multi-drug resistance, WHO: World Health Organization



**Figure 1.** (a) Bone marrow infiltration of a heterogeneous cell population. Large, bizarre tumor cells with surrounding small or medium-sized T lymphocytes and plasma cells (HE staining, x200). (b) CD30-positive large cells in the bone marrow (x200)

g/l, 3.7 g/l and 23.5 g/l, respectively). The IgG and one of IgM paraproteins formed an immune complex, which functioned as a cryoprotein in the medium containing heparin. There was no evidence of infection with hepatitis C virus (HCV) or of HBsAg. Bone marrow biopsy showed heterogeneous cell population (Fig. 1a): epitheloid cells gave a granulomatous appearance intermixed with small and medium-sized T-lymphocytes (CD3 positivity), plasma cells and scattered large, atypical cells with oval-irregular nuclei, broad cytoplasm. The phenotype of atypical cells was CD30+ (Fig. 1b), CD45+/-, CD3+/-, CD15-, CD20-, CD79a-, CD4-, CD8-, Tia-1+/-, ALK1-. Because the phenotype of the large cells was not completely the same as that of the small and medium-sized T lymphocytes, the final diagnosis was anaplastic large cell lymphoma with partial T-phenotype. Cytogenetic examination showed a normal male karyotype. Computed tomographic scan showed no lymphadenopathy, and only a mild hepatosplenomegaly (there was a heavy alcoholism in the patient's past history). The tumor was classified as Ann-Arbor stage IV/B<sub>ES</sub>, the Interna-

tional Prognostic Index was 3. TCR beta- and gamma gene and IgH gene rearrangement polymerase chain reaction revealed a B/T hybrid genotype (Fig. 2) of separated neoplastic cells from the bone marrow. Following standard treatment with CHOP chemotherapy, there was no residual CD30-positive lymphoid involvement in a second bone marrow biopsy. Flow cytometry studies demonstrated the presence of normal bone marrow cells with no evidence of multidrug resistance (MDR) since P-glycoprotein expression was low on CD7-positive cells (10%). The calcein-MDR test also showed poor functional MDR activity. Seven months later he was admitted with fever, fatigue, repeated upper respiratory Candida albicans infection and severe extrapyramidal symptoms. Red blood cell transfusion, antifungal drugs, central nervous system circulation supporting therapy was administered. In spite of this his general condition deteriorated rapidly, and one month later he died of Enterococcus sepsis while still in complete remission from ALCL.



**Figure 2.** IgH gene rearrangement (FR2a/JH) PCR results (a), T-cell receptor gamma gene rearrangement PCR results (b) and t(2;5)(p23;q35) RT-PCR results (c). Vertical arrows show the present case: sharp band at about 230-240 bp representing rearranged IgH gene (a), sharp band at 230 bp representing rearranged TCR gamma gene (b) and smear representing no nucleophosmin/ALK translocation (c). B: blank, P: positive, N: negative, M: molecular marker, bp: base pairs

## Discussion

Anaplastic large cell lymphoma is a heterogeneous group of peripheral T-cell lymphomas. In most cases ALCL affects lymph nodes, while bone marrow involvement only occurs in approximately 10% of cases. The current WHO lymphoma classification system classifies ALCL among T- and null cell phenotype lymphomas while B-cell ALCLs are described as belonging to the category of diffuse large cell lymphomas. The majority of recent studies on ALCL involve immunophenotypic analysis of the tumor cells.<sup>3-5,10,11</sup> Apart from identifying whether there is any involvement of the ALK gene, very little molecular analysis is performed in the neoplastic cells. TCR and IgH gene rearrangement studies can, however, help to identify genotype of problematic cases. An examination of IgH and TCR rearrangement demonstrated the presence of a hybrid B/T genotype in the neoplastic cells. We observed positivity in all three IgH gene rearrangement examinations (FR1c/JH, FR2a/JH and FR3a/JH, by a method published earlier<sup>9</sup>) from bone marrow, which supports the monoclonal origin. There were also rearranged bands by TCR-beta and TCR-gamma PCR (methods published earlier<sup>9</sup>). One possible explanation to account for this is that two malignant clones may have been amplified during repeated PCR examinations. However, IgH gene rearrangement is not restricted to the B-cell lineage, and TCR gene rearrangement can also occur in B-cell lymphoproliferative disorders in 5-20% of cases.<sup>2,9</sup> In the B-lineage cases the tumor infiltrating oligoclonal T lymphocytes or in both cases the surrounding polyclonal cells can coamplify during the PCR analysis. The single cell gene rearrangement study can prove the origin of monoclonal cells. B-cell clonal expansion can develop in antigen-driven B-cell proliferation. In the cases of HCV-induced cryoglobulinemia, IgH gene rearrangement is often positive. In our presented case HCV serology and PCR examination were negative in spite of cryoglobulinemia (IgG and IgM immune complex). The origin of IgH gene rearrangement of our case is not clear. The malignant T cells could produce cytokines stimulating clonal B cells responsible for triple M gradient.

Therapy of primary bone marrow lymphoma is a great challenge because of serious bone marrow toxicity. CHOP therapy was therefore chosen to avoid dangerous myelotoxicity. During the 6 cycles of chemotherapy the patient had no hemosubstitution requirement; his general condition improved and the B-symptoms disappeared. The patient later died of infection due to impaired cellular and humoral immune response. Our presented patient had an extremely rare case history of primary bone marrow ALK-negative T-cell ALCL in association with triple M gradient producing cryoglobulin without HCV infection.

## References

1. Falini B, Pileri S, Zinzani PL, Carbone A, Zagonel V, Wolf-Peters CD, Verhoef G, Manestrina F, Tedeschini G, Paulli M, Lazzarino M, Giardini R, Aiello A, Foss HD, Araujo I, Fizzotti M, Pelicci PG, Flenghi L, Martelli MF, Santucci A: ALK<sup>+</sup> lymphoma: clinico-pathological findings and outcome. *Blood* 93: 2697-2706, 1999
2. Garcia MJ, Martinez-Delgado B, Granizo JJ, Benitez J, Rivas C: IgH, TCR-gamma, and TCR-beta gene rearrangement in 80 B- and T-cell non-Hodgkin's lymphomas: study of the associations between proliferation and so-called „aberrant” patterns. *Diagn Mol Pathol* 10: 69-77, 2001
3. Greer JP, Kinney MC, Collins RD, Sathany KE, Wolff SN, Hainsworth JD, Flexner JM, Stein RS: Clinical features of 31 patients with Ki-1 anaplastic large-cell lymphoma. *J Clin Oncol* 9: 539-547, 1991
4. Lamant L, Meggetto F, Al Saati T, Brugieres L, Paillerets BB, Dastugue N, Bernheim A, Rubie H, Terrier-Lacombe J, Robert A, Brousset P, Rigal F, Schlaifer D, Shiota M, Mori S, Delsol G: High incidence of the t(2;5)(p23;q35) translocation in anaplastic large cell lymphoma and its lack of detection in Hodgkin's disease. Comparison of cytogenetic analysis, reverse transcriptase-polymerase chain reaction, and P-80 immunostaining. *Blood* 87: 284-291, 1996
5. Longo G, Federico M, Pieresca C, Avanzini P, Iannito E, Di Prisco AU, Baldini L, Brugiattelli M, Clo V, Bevini M, Silingardi V: Anaplastic large cell lymphoma (CD30+/Ki-1+). Analysis of 35 cases followed at GISL centres. *Eur J Cancer* 31A: 1763-1767, 1995
6. Shulman LN, Frisard N, Antin JH, Wheeler C, Pinkus G, Magauran N, Mauch P, Nobles E, Mashal R, Canellos G, Tung N, Kadin M: Primary Ki-1 anaplastic large-cell lymphoma in adults: clinical characteristics and therapeutic outcome. *J Clin Oncol* 11: 937-942, 1993
7. Stein H, Foss HD, Dürkop H, Marafioti T, Delsol G, Pulford K, Pileri S, Falini B: CD30+ anaplastic large cell lymphoma: a review of its histopathologic, genetic and clinical features. *Blood* 96: 3681-3695, 2000
8. Szomor Á, Molnár L, Iványi J, Radványi G, Nagy Z, Karádi Á, Gergely L, Bányai A, Demeter J, Aryan H, Gasztonyi Z, Kiss A, Kollár B, Egyed M, Losonczy H, Kelényi G, Pajor L: Extranodal involvement in primary systemic anaplastic large cell lymphoma (ALCL) in adults. *Ann Hematol* 80: B144-145, 2001
9. Theriault C, Galoin S, Valmary S, Selves J, Lamant L, Roda D, Rigal-Huguet F, Brousset P, Delsol G, Al Saati T: PCR analysis of immunoglobulin heavy chain (IgH) and TcR-gamma chain rearrangements in the diagnosis of lymphoproliferative disorders of a study of 525 cases. *Mod Pathol* 13: 1269-1279, 2000
10. Tilly H, Gaulard P, Lepage E, Dumontet C, Diebold J, Plantier I, Berger F, Symann M, Pertella T, Lederlin P, Briere J: Primary anaplastic large-cell lymphoma in adults: clinical presentation, immunophenotype, and outcome. *Blood* 90: 3727-3734, 1997
11. Zinzani PL, Bendandi M, Martelli M, Falini B, Sabbatini E, Amadori S, Gherlinzoni F, Martelli MF, Mandelli F, Tura S, Pileri SA: Anaplastic large-cell lymphoma: prognostic evaluation of 90 adult patients. *J Clin Oncol* 14: 955-962, 1996